The Research of Medical Science Review
ISSN: 3007-1208 & 3007-1216 Volume 3, Issue 6, 2025

SPINAL DROP METASTASIS IN GLIOBLASTOMA MULTIFORME: A RARE CLINICAL CASE

Muhammad Haad Arif[*1], Sadia Abdullah[2], Jawad Latif[3], Anusha Haider[4], Saleha Yaqoob[5], Hamna Arif[6]

*[*1,2,3,4,5,6]Department of Clinical and Radiation Oncology, Shaukat Khanum Memorial Caner Hospital and Research Centre, Lahore, Pakistan*

DOI: https://doi.org/10.5281/zenodo.17678659

Keywords

Article History
Received on 23 May 2025
Accepted on 23 June 2025
Published on 30 June 2025

Copyright @Author
Corresponding Author: *
Muhammad Haad Arif

Abstract

Glioblastoma multiforme (GBM), a Grade IV tumor, is the most common malignant primary brain tumor, comprising 12% to 15% of all intracranial neoplasms. With a global incidence of 2–3 cases per 100,000 people, it remains highly aggressive, with an average survival time of about 15 months despite advances in treatment.

Traditionally, GBM was thought to be non-metastatic, largely due to physiological barriers protecting the central nervous system. Spinal metastasis is estimated to occur in 2%–5% of patients with Glioblastoma Multiforme (GBM). However, this figure likely underestimates the actual prevalence of spinal metastases in GBM, as many patients may die before these metastases are clinically detected. Consequently, the true prevalence could be higher than documented.

We intend to present the case of a 33-year-old male who experienced headaches and vomiting over several months before being diagnosed with Glioblastoma Multiforme (GBM). After diagnosis, he underwent surgical resection of the tumor and was treated with adjuvant radiotherapy. While undergoing adjuvant chemotherapy, an MRI of the spine revealed a rather rare presentation of spinal drop metastasis at the T4 level.

INTRODUCTION

Glioblastoma multiforme (GBM) is an exceptionally aggressive and malignant brain tumor, representing the most prevalent form of primary brain cancer in adults. Known for its rapid growth and extensive infiltration into surrounding brain tissue, GBM presents considerable treatment challenges. It most commonly affects individuals between the ages of 40 and 60 and is associated with a poor prognosis, with a median survival of approximately 15 to 18 months despite aggressive treatment modalities such as surgery, radiation, and chemotherapy. Ongoing research aims to enhance treatment outcomes and discover new therapeutic approaches.

A rare but significant complication of GBM is the development of spinal drop metastases. Although not frequently encountered, these metastases can emerge, particularly in the advanced stages of the disease. They usually result from GBM cells spreading through the cerebrospinal fluid (CSF) or by direct extension from the primary brain tumor, leading to secondary tumor growth in the spinal cord or CSF spaces. Patients may present with symptoms such as back pain, leg weakness, and neurological deficits, including difficulty walking or incontinence. Diagnosis typically involves MRI of the spine and CSF analysis to identify tumor cells. Treatment often includes a combination of radiation therapy and chemotherapy, with surgical

options considered for symptomatic relief or removal of localized spinal lesions.

The prognosis for GBM with spinal drop metastases is generally poor, reflecting the disease's aggressive nature and the complexities of managing these secondary tumors. The presence of spinal metastases, though relatively rare, indicates advanced disease and extensive tumor dissemination, complicating treatment and often resulting in more widespread and difficult- to-treat lesions.

Managing GBM remains highly challenging, with the primary treatment strategy focusing on maximal safe surgical resection, followed by postoperative radiotherapy and adjuvant chemotherapy as the standard of care. There is no well-defined treatment protocol for extracranial metastases. Given the typically poor prognosis associated with distant dissemination, surgical intervention may be considered based on the patient's oncological and functional status. While the outlook for such metastases is generally bleak, accurate diagnosis and targeted treatment can provide palliative benefits and potentially enhance the patient's quality of life.

Case

This case report describes a 33-year-old married South Asian male, with a history of treated pulmonary tuberculosis, no known allergies, and no family history of cancer. He initially presented with headaches, vomiting, and seizures over the past 6 to 7 months. These symptoms were initially sporadic and managed with over-the-counter medications, but they gradually worsened. Diagnostic tests at a local hospital revealed a diagnosis of Glioblastoma Multiforme (GBM) Grade IV glioma. Imaging showed a solitary, complex, predominantly cystic/necrotic lesion measuring 3 x 3 cm in the right frontal lobe with surrounding edema.

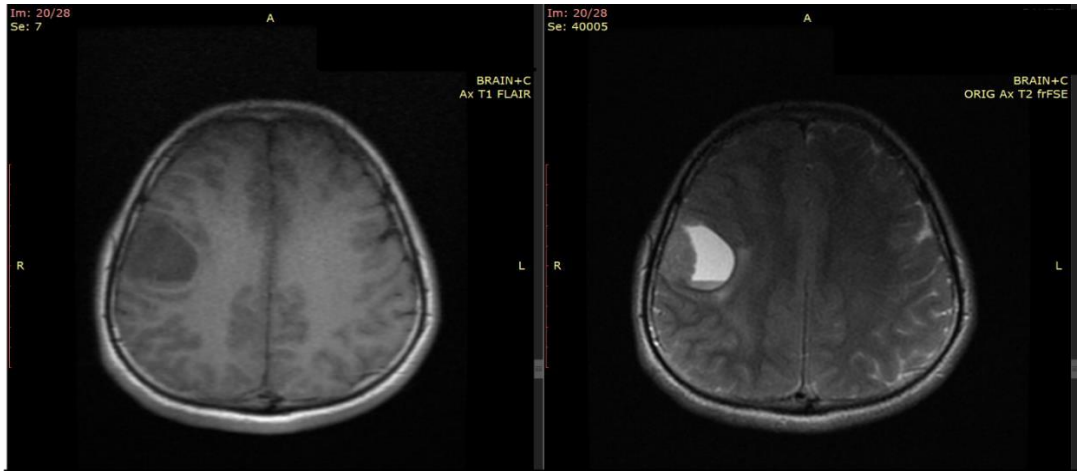

Figure 1 cystic/necrotic lesion measuring 3 x 3 cm in the right frontal lobe with surrounding edema

A surgical resection of the tumor in the right frontal lobe was performed, and the histopathological examination confirmed a high-grade glioma, CNS WHO Grade IV, IDH wild type. Post-operative MRI indicated potential residual disease. After consultation with the Neuro-oncology Multidisciplinary Team (MDT), the patient underwent radiotherapy, receiving 60 gray in 30 fractions. Temozolamide could not be given in concurrent or adjuvant setting due to financial constraints.

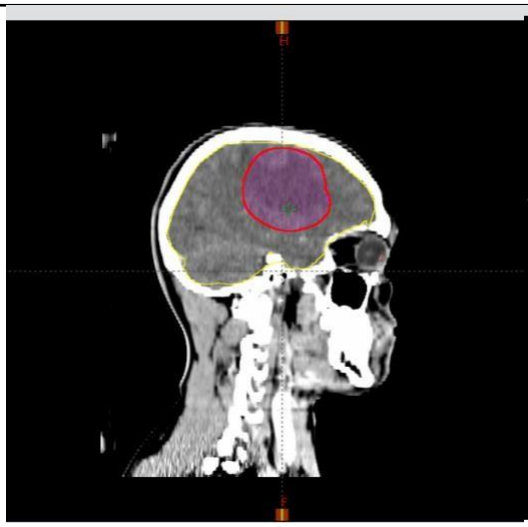

Figure 2(sagittal) Planning volume for GBM

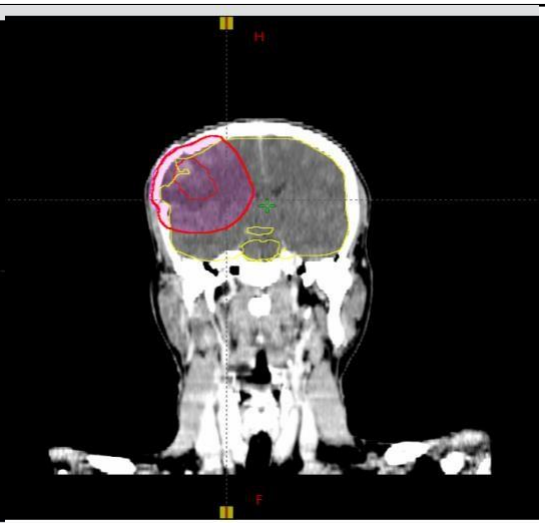

Figure 3(coronal) Planning volume for GBM

Following surgery and radiotherapy, the patient's symptoms improved, allowing him to resume normal daily activities with optimism for recovery. He began adjuvant PCV chemotherapy but only completed 3 cycles before presenting to the emergency department with seizures, right-sided facial deviation, back pain, and paresthesia in both hands. Steroids with a proton pump inhibitor (PPI) were started, and an MRI of the whole spine was performed, revealing a T2 high signal, STIR intermediate signal extra medullary intra dural lesion at T4, causing mass effect on the spinal cord and effacing the posterior thecal sleeve.

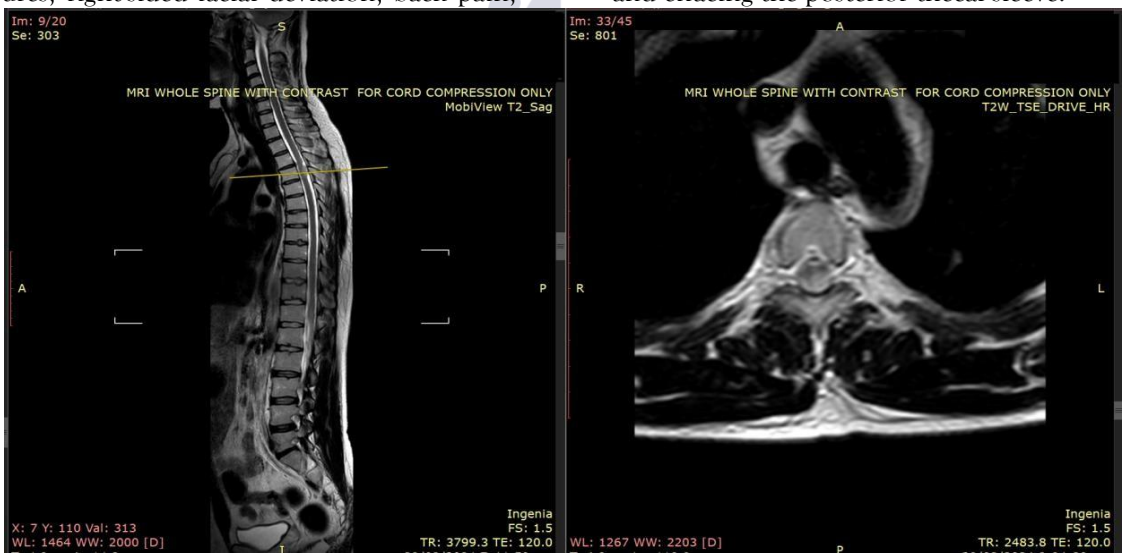

Figure 4 T2 high signal, STIR intermediate signal extra medullary intra dural lesion at T4, causing mass effect on the spinal cord and effacing the posterior thecal sleeve.

A CT scan of the chest, abdomen, and pelvis showed no other metastatic sites. The patient was admitted for inpatient care and reviewed by neurosurgery. As no surgical intervention was deemed appropriate, clinical oncology was consulted. The possibility of drop metastasis from the known high-grade glioma was discussed with the patient and family, and the patient received 20 gray in 5 fractions targeted at the spinal lesion. There was an 8-month interval between the GBM diagnosis and the detection of spinal drop metastasis in this case.

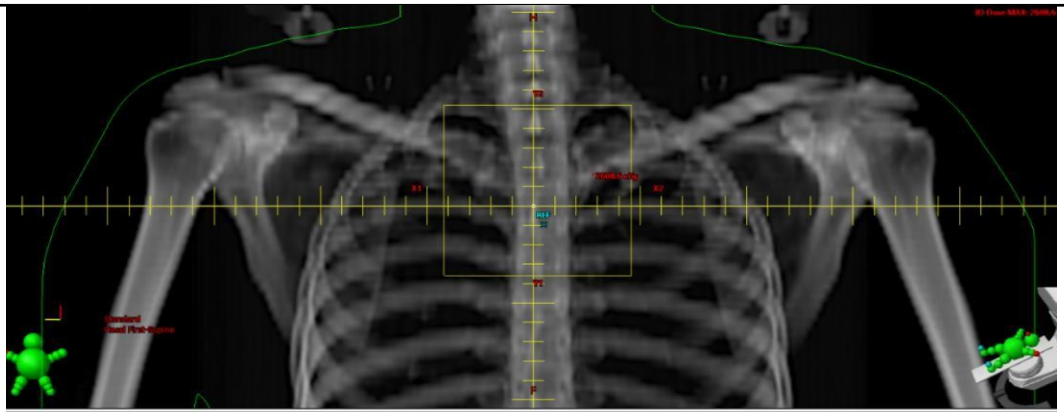

Figure 4 (above and below):: Virtual simulation field for spinal drop metastasis at T4



During admission, an MRI of the brain showed further disease progression, with new lesions in the right thalamus and nodular enhancement of the basal meninges. The patient was subsequently referred to palliative care for further management. Unfortunately, he passed away 2 months later.

Discussion

In this case report, a 33-year-old male with a history of treated pulmonary tuberculosis presented with glioblastoma multiforme (GBM), a highly aggressive brain tumor. His initial symptoms—headaches, vomiting, and seizures—worsened progressively over 6-7 months, leading to the diagnosis of GBM. Neuroimaging revealed a complex cystic/necrotic lesion in the right frontal lobe, which was surgically resected, followed by 60 Gy in 30 fractions of radiotherapy. Post-surgical imaging showed potential residual disease, and the patient began adjuvant PCV chemotherapy. However, after completing three cycles of chemotherapy, he presented with seizures, right-sided facial deviation, back pain, and paresthesia. Spinal MRI revealed a T4 extra-medullary intra-dural lesion, suggestive of spinal metastasis, which was confirmed after further diagnostic evaluation.

The occurrence of spinal metastasis in GBM is rare, with most metastatic spread occurring within the central nervous system, particularly the brain (Kim & Chang, 2017; Bertani et al., 2020). Spinal metastasis, although well-documented in cancers like breast, lung, and prostate, is infrequent in GBM. This is supported by studies such as those by Yao et al. (2021), which show that spinal metastasis occurs late in the disease course, often after widespread dissemination. In the current case, the spinal metastasis developed just 8 months after the initial GBM diagnosis, a relatively short interval compared to other reports, such as those by Brar & Papadopoulos (2019), where spinal

metastasis appeared much later in the course of the disease.

Additionally, the treatment protocol followed in this case—surgical resection, radiotherapy, and adjuvant PCV chemotherapy—is consistent with standard GBM management. However, the inability to administer Temozolomide (TMZ) due to financial constraints is noteworthy and differs from the typical treatment regimens emphasized in the literature, where TMZ is a cornerstone of therapy (Aiken & Starks, 2019; Yao et al., 2021). The patient's condition improved following surgery and radiotherapy, but the detection of spinal metastasis after chemotherapy highlights the aggressive nature of GBM. Radiation therapy to the spinal lesion (20 Gy in 5 fractions) was used as the primary treatment, a strategy commonly employed in metastatic cases (Bertani et al., 2020; Kim & Chang, 2017).

In terms of prognosis, GBM remains one of the most aggressive and fatal brain cancers, with a median survival of approximately 14-18 months despite treatment (Schmidt et al., 2016). The development of spinal metastasis significantly worsens the prognosis, as it indicates widespread dissemination of the disease. This case, like others documented by Brar & Papadopoulos (2019), underscores the challenges in managing GBM, especially when faced with uncommon metastatic spread, financial limitations, and the aggressive progression of the disease.

In conclusion, this case highlights the rarity of spinal metastasis in GBM, adding to the limited body of literature on the topic (De Bonis et al., 2017). It also emphasizes the need for careful monitoring for distant metastases in patients with GBM and the clinical challenges posed by resource limitations in developing countries. Further studies are needed to understand the mechanisms and optimal treatment strategies for spinal metastasis in GBM.

Conclusion

The presence of spinal drop metastases in glioblastoma multiforme (GBM) significantly worsens prognosis. Early detection is essential for effective management; clinicians should perform comprehensive evaluation, including cerebrospinal fluid (CSF) analysis and advanced imaging like MRI spine in conjunction with brain imaging, to identify early spinal involvement. This case underscores the critical need for early detection and a multifaceted treatment approach, emphasizing the importance of ongoing research into more effective therapies and the benefits of early intervention and multidisciplinary care.

REFERENCES

Birbilis, Theodossios A. MD, PhD; Matis, Georgios K. MD, MSc, PhD; Eleftheriadis, Savvas G. PhD; Theodoropoulou, Efthimia N. PhD; Sivridis, Efthimios MD, PhD. Spinal Metastasis of Glioblastoma Multiforme: An Uncommon Suspect?. Spine 35(7):p E264- E269, April 1, 2010. | DOI: 10.1097/BRS.0b013e3181c11748

Sibanda Z, Farahani N, Ogbonnaya E, Albanese E. Glioblastoma multiforme: a rare case of spinal drop metastasis. World Neurosurg 2020;144:24-27.

Veerwal H, Meena A, Dhingra V. A Case of Extracranial Metastasis of Glioblastoma Multiforme Seen on Bone Scintigraphy. Mol Imaging Radionucl Ther. 2022 Oct;31(3):246-249. doi:10.4274/mirt.galenos.2021.09815.

Jimmy Achi1, Xavier Wong Achi2, Paula Veintimilla3, Janina Cueva4. Unusual extra neural metastasis of glioblastoma. 23-Jun-2023;14:218.

Aiken, L. G., & Starks, L. (2019). Spinal metastasis of glioblastoma multiforme: Case report and literature review. Neuro-Oncology Practice, 6(4), 199-203

Bertani, G., Beretta, G., & Di Meco, F. (2020). Spinal metastasis in glioblastoma multiforme: A rare event and review of the literature. Journal of Neurosurgery, 133(2), 404-411.

Brar, H. S., & Papadopoulos, M. (2019). Spinal metastases from glioblastoma multiforme: A case report and a review of literature. Journal of Spine Surgery, 5(2), 158-162.

De Bonis, P., & Anile, C. (2017). Spinal metastases in glioblastoma multiforme: Case report and review of the literature. Acta Neurochirurgica, 159(2), 233-239.

Kim, Y. J., & Chang, J. H. (2017). Spinal cord metastasis in glioblastoma: A rare complication. World Neurosurgery, 98, 830-836.

Schmidt, M., & Capelle, L. (2016). Spinal cord metastasis in glioblastoma multiforme: A rare but significant clinical entity. Journal of Neuro-Oncology, 127(3), 473-478.

Yao, R. K., & Zhang, M. (2021). Clinical characteristics and outcomes of spinal metastasis from glioblastoma multiforme: A systematic review. Journal of Neuro- Oncology, 151(3), 437-444..

IEER
Institute for Excellence in Education & Research