

## DIAGNOSTIC ACCURACY OF ULTRASOUND IN DETECTING PLACENTA ACCRETA USING INTRAOPERATIVE FINDINGS AS THE GOLD STANDARD

Dr. Aqsa Azhar<sup>1</sup>, Laiba Azhar<sup>2</sup>, Dr. Nazia Mussarat<sup>3</sup>, Dr. Muhammad Salman Zaheer<sup>4</sup>  
Dr. Amaima Gulzar<sup>5</sup>, Dr. Fareeha Shahid<sup>6</sup>

<sup>1</sup>MBBS, FCPS PGR Obstetrics and Gynecology, Aziz Fatima Hospital, Faisalabad

<sup>2</sup>MBBS, Medical Student, King Edward Medical University, Lahore

<sup>3</sup>MBBS, FCPS, Professor of Obstetrics and Gynecology, Aziz Fatima Hospital, Faisalabad

<sup>4</sup>MBBS, FCPS radiology, Consultant Radiologist, Aziz Fatima Hospital, Faisalabad

<sup>5</sup>MBBS, FCPS PGR, Shifa International hospital, Islamabad

<sup>6</sup>Associate Prof, Department of Community Medicine, Baharia University of Health Sciences Karachi

DOI: <https://doi.org/10.5281/zenodo.19449716>

### Keywords

Placenta Accreta; Sensitivity and Specificity; Ultrasonography; Vascularity

### Article History

Received on 14 March 2025  
Accepted on 22 March 2025  
Published on 25 March 2025

Copyright @Author

Corresponding Author: \*  
Dr. Aqsa Azhar

### Abstract

**Objective:** To determine the diagnostic accuracy of ultrasound in detecting placenta accreta, with the aim of facilitating early diagnosis, appropriate management, and reduction of maternal morbidity.

**Study Design:** Cross-sectional study.

**Study Setting:** Department of Obstetrics and Gynecology

**Study Duration:** Six Months (July'24 to January'25 )

**Methodology:** total of 205 high-risk pregnant women, aged 20–40 years, suspected of placenta accreta were included in the study. Exclusion criteria were primigravida, unintentional bleeding, gestational age under 28 weeks, and posterior placenta location. To evaluate the varying utero-placental vascularity, a Color Doppler scan was conducted. If the placenta was easily removed without bleeding during surgery, it was considered normal; however, if the placenta was difficult to remove and there was considerable bleeding ( $\geq 1000$ cc), it was deemed placenta accreta. Ultrasound findings were then compared with intraoperative results to evaluate the diagnostic accuracy of ultrasonography.

**Results:** Using intraoperative findings as the gold standard, the overall sensitivity, specificity, positive predictive value, negative predictive value, and diagnostic accuracy of ultrasonography for placenta accreta diagnosis were 90.43%, 93.33%, 94.55%, 88.42%, and 91.70%, respectively.

**Conclusion:** Ultrasonography is a sensitive and accurate modality for placenta accreta identification. It has significantly increased our capacity to identify the condition and, as a result of its precise diagnosis, has also improved patient care.

### INTRODUCTION

Abnormal placental trophoblast adhesion to the uterine myometrium is generally referred to as placenta accreta spectrum (PAS), or morbidly adherent placenta. Depending on the extent of

trophoblast invasion into the myometrium, it is divided into three subtypes: placenta accreta, placenta increta, and placenta percreta.<sup>1</sup> Placenta accreta is currently the leading peripartum

hysterectomy cause and a significant contributor to maternal morbidity and mortality. Although the precise cause is unknown, damage to the decidua basalis has been suggested as a contributing factor, as it permits the placenta to target the myometrium. Therefore, management requires a coordinated interprofessional approach. Hence collaborative and multidisciplinary approach is essential for management.<sup>2</sup>

Previous cesarean delivery, placenta previa, maternal age over 35, uterine instrumentation, and intrauterine scar are recognized risk factors for placenta accreta. These conditions may be linked to damage to or absence of the decidua basalis.<sup>3</sup> Obstetricians take appropriate precautions and maintain a high index of suspicion for placenta accreta when these risk factors are present. Serious internal bleeding associated with placenta accreta may result in maternal or fetal death. The incidence of placenta accreta has significantly increased over the last several decades. In women who have had prior cesarean sections and anterior low-lying placentas, this syndrome should be considered in the differential diagnosis.

Optimal management of a morbidly adherent placenta relies on accurate prenatal diagnosis, which ensures the availability of blood products and a qualified surgical team, anesthetist, and interventional radiologist. The main method for ruling out placenta accreta is transabdominal sonography, although this method has technical limitations. False-positive results can be caused by posterior placentation, maternal obesity, myometrial contraction, or bladder distention.<sup>4, 5</sup> Histological characteristics, imaging results, and clinical history are typically used to diagnose placenta accreta. Doppler ultrasonography is the next imaging method utilized when abdominal ultrasonography is unable to rule out placenta accreta as a diagnosis.<sup>6, 7</sup>

To date, PAS has been diagnosed using both magnetic resonance imaging (MRI) and ultrasound (US). However, due to its widespread availability and low cost, ultrasonography should be the first-line approach for PAS diagnosis, according to International Federation of Gynecology and Obstetrics (FIGO) consensus guidelines. Although MRI is not always required for prenatal diagnosis, it can be a helpful tool to clarify equivocal ultrasound

findings or to determine the pelvic extension of placenta percreta.<sup>6, 7</sup>

Maged et al has also studied the diagnostic accuracy of ultrasound in detecting placenta accreta eliciting the sensitivity, specificity, negative likelihood ratio and positive likelihood ratio of 87.03%, 86.34%, 0.155 and 4.99 respectively. He also analysed individual ultrasound characteristics of placenta accreta establishing the highly specific indicator to be uterovesical hypervascularity having the specificity of 0.994.<sup>8</sup>

Given the life-threatening nature of placenta accreta, this study aims to determine the diagnostic accuracy of ultrasound in its detection, as ultrasound is readily available and may aid in early detection, facilitating appropriate management and reducing morbidity associated with placenta accreta.

## METHODOLOGY:

A total of 205 women with suspicion of placenta accreta who visited the Department of Obstetrics and Gynecology at Aziz Fatima Hospital in Faisalabad, between July 2024 and January 2025, were included in this cross-sectional study. The sample size was determined using the following criteria: a 95% confidence level, a 10% desired precision, a 28.0% prevalence of placenta accreta, and reported ultrasound sensitivity and specificity of 85.7% and 83.3%, respectively, for its diagnosis on ultrasound. Exclusion criteria included primigravida status, unintentional bleeding, gestational age under 28 weeks, and posterior location of placenta.

Patients who met inclusion and exclusion criteria were enrolled following approval by the ethical review committee of the Aziz Fatima hospital (letter approval number: IEC/280-23, Dated: 14/10/2023). Patients gave their written informed consent. After the 28th week of pregnancy, all patients underwent detailed history taking, comprehensive general and local examinations, standard laboratory investigations, and transabdominal as well as transvaginal ultrasound, with particular attention to the placental site, grade, and degree of attachment. In order to properly assess bladder wall attachment and uterine serosa, patients were instructed to partially fill their bladders. Myometrial thickness was measured at the site of placental implantation, and the first placental homogeneity was evaluated using the grayscale ultrasonography. The varied utero-

placental vascularity was then evaluated using color Doppler. If placenta was easily removed without bleeding during surgery, it was regarded normal; however, if the placenta was difficult to remove and there was considerable bleeding ( $\geq 1000\text{cc}$ ), it was deemed placenta accreta. The intraoperative diagnosis of placenta accreta was compared with ultrasonography findings to evaluate its diagnostic precision. Every piece of information was entered into a pre-made proforma.

SPSS V-25 was used to enter all of the data. For every quantitative variable, including age, gestational age, gravidity, parity, and prior C-sections number, the mean and standard deviation were computed. For each qualitative feature, including history of myomectomy or curettage, placenta accreta on ultrasonography or intraoperatively, frequencies and percentages were computed. Using intra-operative findings as the gold standard, a 2x2 contingency table was utilized to calculate the sensitivity, specificity, positive predictive value (PPV), negative predictive value (NPV), and overall diagnostic accuracy of ultrasonography.

#### RESULTS:

A total of 205 pregnant women with suspected placenta accreta were included in this study. The demographic characteristics of the participants are presented in Table 1. Among the study participants, 97 (47.32%) women were aged 20–30 years, while 108 (52.68%) were aged 31–40 years. Regarding gestational age, 147 (71.72%) women were between 37–39 weeks of gestation, whereas 58 (28.28%) were between 40–41 weeks.

With respect to obstetric history, 140 (68.29%) women had gravidity  $\leq 2$ , while 65 (31.71%) had gravidity  $> 2$ . In terms of parity, 135 (65.85%) women had parity  $\leq 2$ , and 70 (34.15%) had parity  $> 2$ . Similarly, 135 (65.85%) women had fewer than two previous cesarean sections, while 70 (34.15%) had two or more previous cesarean sections.

The diagnostic accuracy of ultrasound in detecting placenta accreta was evaluated by comparing ultrasound findings with intraoperative findings, as shown in Table 2. Ultrasound correctly identified 104 true positive cases and 84 true negative cases. There were 6 false positive cases and 11 false negative

cases. The sensitivity of ultrasound was 90.43%, while the specificity was 93.33%. The positive predictive value (PPV) was 94.55%, and the negative predictive value (NPV) was 88.42%. The likelihood ratio for a positive test result was 13.57, and the likelihood ratio for a negative test result was 0.10. The overall diagnostic accuracy of ultrasound for the detection of placenta accreta was 91.70%.

Stratification of diagnostic accuracy according to different study variables is shown in Table 3. When stratified by age, the sensitivity and specificity among women aged 20–30 years were 91.84% and 93.75%, respectively, with an overall diagnostic accuracy of 92.78%. Among women aged 31–40 years, sensitivity was 89.39%, specificity was 92.86%, and diagnostic accuracy was 90.74%.

Regarding gestational age, women with gestational age 37–39 weeks showed a sensitivity of 92.59%, specificity of 93.94%, and diagnostic accuracy of 93.20%, while those with 40–41 weeks of gestation showed a sensitivity of 85.29%, specificity of 91.67%, and diagnostic accuracy of 87.93%. When stratified according to gravidity, women with gravidity  $\leq 2$  had a sensitivity of 91.78%, specificity of 92.54%, and diagnostic accuracy of 92.14%, whereas women with gravidity  $> 2$  showed a sensitivity of 88.10%, specificity of 95.65%, and diagnostic accuracy of 90.77%.

Similarly, among women with parity  $\leq 2$ , the sensitivity, specificity, and diagnostic accuracy were 92.65%, 91.04%, and 91.85%, respectively. Among those with parity  $> 2$ , sensitivity was 87.23%, specificity was 100%, and diagnostic accuracy was 91.43%.

Finally, stratification according to previous cesarean sections showed that women with fewer than two previous cesarean sections had a sensitivity of 98.60%, specificity of 93.75%, and diagnostic accuracy of 96.30%. In contrast, women with two or more previous cesarean sections had a sensitivity of 77.27%, specificity of 92.31%, and diagnostic accuracy of 82.86%. Figure I demonstrates the diagnostic performance of ultrasonography in detecting placenta accreta. The Area Under the Curve (AUC) was 0.919 (95% CI: 0.88–0.957;  $p < 0.001$ ), indicating excellent discriminative ability.

TABLE 1: DEMOGRAPHIC CHARACTERISTICS OF STUDY PARTICIPANTS (N = 205)

Variable	Category	Frequency	Percentage
Age (years)	20–30	97	47.32%
	31–40	108	52.68%
Gestational Age (weeks)	37–39	147	71.72%
	40–41	58	28.28%
Gravidity	≤2	140	68.29%
	>2	65	31.71%
Parity	≤2	135	65.85%
	>2	70	34.15%
Previous C-sections	<2	135	65.85%
	≥2	70	34.15%

TABLE 2: DIAGNOSTIC ACCURACY OF ULTRASOUND FOR PLACENTA ACCRETA (N = 205)

Ultrasound Findings	Placenta Accreta Present	Placenta Accreta Absent
Positive	104	6
Negative	11	84

Sensitivity: 90.43%

Specificity: 93.33%

Positive Predictive Value (PPV): 94.55%

Negative Predictive Value (NPV): 88.42%

Likelihood ratio for positive test result: 13.57

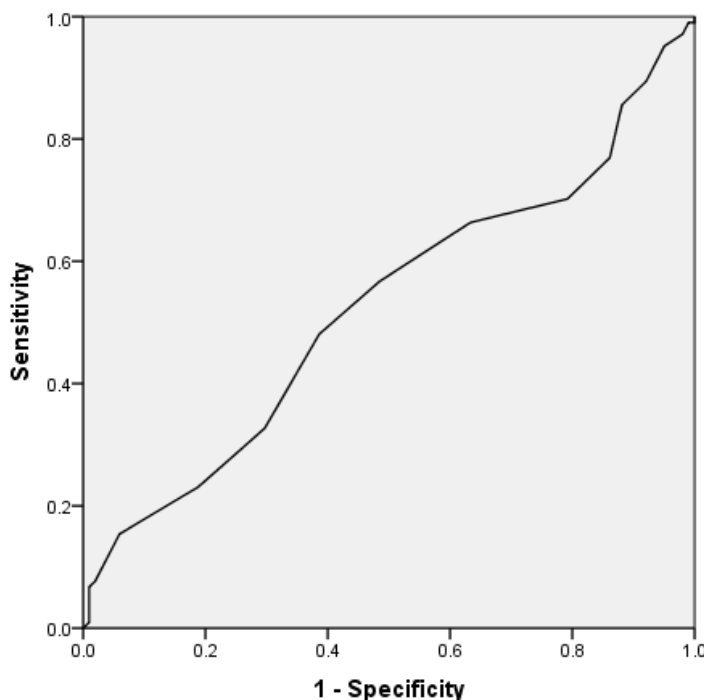
Likelihood ratio for negative test result: 0.10

Diagnostic Accuracy: 91.70%

TABLE 3: STRATIFICATION OF DIAGNOSTIC ACCURACY OF ULTRASOUND ACCORDING TO STUDY VARIABLES

Variable	Category	TP	FP	FN	TN	Sensitivity	Specificity	Diagnostic Accuracy
Age (years)	20–30	45	3	4	45	91.84%	93.75%	92.78%
	31–40	59	3	7	39	89.39%	92.86%	90.74%
Gestational Age (weeks)	37–39	75	4	6	62	92.59%	93.94%	93.20%
	40–41	29	2	5	22	85.29%	91.67%	87.93%
Gravidity	≤2	67	5	6	62	91.78%	92.54%	92.14%
	>2	37	1	5	22	88.10%	95.65%	90.77%
Parity	≤2	63	6	5	61	92.65%	91.04%	91.85%
	>2	41	0	6	23	87.23%	100%	91.43%
Previous C-Sections	<2	70	4	1	60	98.60%	93.75%	96.30%
	≥2	34	2	10	24	77.27%	92.31%	82.86%

FIGURE I: ROC CURVE



## DISCUSSION:

No single diagnostic technique can completely ascertain whether or not placenta accreta is present, even with advanced imaging technology.<sup>9</sup> Using intraoperative results as the gold standard, this study was conducted to determine the diagnostic accuracy of ultrasound for placenta accreta. A Doppler ultrasonography was performed on each patient. Using intraoperative findings as the gold standard, the overall sensitivity, specificity, positive and negative predictive values, and ultrasound's diagnostic accuracy for placenta accreta diagnosis were 90.43%, 93.33%, 94.55%, 88.42%, and 91.70%, respectively.

Amirabi A and colleagues demonstrated the utility of Doppler ultrasonography in placental localization and identification of adherent placenta in 150 singleton pregnant women with a gestational age of  $\geq 24$  weeks with history of uterine incision (cesarean section, myomectomy, or metroplasty). Due to severe hemorrhage and a morbidly adherent placenta, twelve patients underwent cesarean-hysterectomy. Histopathology reports showed seven cases of placenta accreta, three cases of placenta increta, and one case of placenta percreta. Doppler ultrasonography depicted a sensitivity of 91.67%, specificity of 100%, positive predictive value of 100%, and negative predictive value of 99.28% in this study.<sup>10</sup>

Another report highlighted the pooled sensitivities and specificities for individual ultrasound markers used to diagnose placenta accreta spectrum (PAS). Placental lacunae demonstrated a sensitivity of approximately 78.43% and specificity of 96.03%, while loss of the hypoechoic space (myometrial thinning or loss of the clear zone) demonstrated a sensitivity of around 67.25% and specificity of 96.77%. For the bladder and uterus interface abnormalities with sensitivity of 50.67% and extremely high specificity of 99.77% were the loss of bladder wall echogenicity. Moreover, color Doppler findings of increased intraplacental vascularity or turbulent flow with a sensitivity of 91.75% and specificity of 88.69% are of considerable diagnostic value for the diagnosis of PAS.<sup>11</sup>

The presence of multiple vessels on 3D power Doppler was found to be the most sensitive single sign of placenta accreta, supporting the conclusion

that 3D power Doppler is a useful diagnostic tool for MAP.<sup>12</sup> The conclusion was most affected by the grade of placental lacunae, with grade 3 lacunae exhibiting the highest invasion score and the most moderate interobserver agreement.<sup>13</sup>

In a recent study, Juan Clar et al. examined various ultrasound criteria like myometrial thinning  $< 1$ mm and loss of hypoechoic retroplacental zone in detection of placenta accreta spectrum. 10 out of 11 cases were accurately established with a sensitivity, specificity, PPV, NPV of 90.9%, 98.3%, 83.3% and 99.15 respectively using an established protocol. Those who had confirmed cases of PAS had more than three positive criteria. The identification of lacunar images and hypervascularization as significant predictors emphasizes the importance of myometrial evaluation in a multi-criteria ultrasound assessment.<sup>14</sup>

Over 10 years and with a sample of 57,164 pregnancies, contingent ultrasound screening for PAS identified 21 of 22 cases in women with placenta previa and a history of uterine surgery (sensitivity 95.5%, specificity 100%). When linked to specialized PAS care, targeted screening was proven feasible and precise, effectively decreasing maternal morbidity.<sup>15</sup>

A review of 18 studies including 861 pregnancies diagnosed with placental accreta suggest that ultrasound (US) and magnetic resonance imaging (MRI) offer comparable accuracy in diagnosing PAS. Pulsed data showed no substantial differences in sensitivity (US 0.90, MRI 0.89) and specificity (US 0.83, MRI 0.87). MRI is said to be of no value in PAS diagnosis due to cost, yet incorporating ultrasound, MRI, and clinical risk factors may enhance prenatal diagnosis.<sup>16</sup> Color Doppler ultrasound accurately diagnosed placenta accreta in 50 pregnancies, 45 of which were confirmed accreta cases by histopathology. Its sensitivity, specificity, positive predictive value, and negative predictive value were 89.4%, 90.4%, 84.0%, and 93.7%, respectively. As such, Color Doppler is a valuable tool for antenatal diagnosis and helps to improve preoperative planning.<sup>17</sup>

For 79 women classified as high-risk, second-trimester ultrasounds yielded a sensitivity of 51.6% and a specificity of 79.2% for PAS. In contrast, third-trimester scans achieved 90% sensitivity, although

specificity dropped to 60.8%. High-risk patients received additional third-trimester scans to allow for a more accurate assessment and to enhance the safety of delivery planning.<sup>18</sup> Research conducted on 90 women revealed that 3D-TUI and 3D power Doppler, according to Alalfy criteria, accurately differentiated PAS from non-adherent placenta and assessed invasion along with vasculature patterns with 100% and 98.8% accuracy, respectively.<sup>19</sup>

A review and meta-analysis of 17 studies involving 1,301 women with PAS risk factors compared ultrasound with MRI for the diagnosis of PAS. The overall accuracy was similar for both modalities—ultrasound (sensitivity 83.3%, specificity 83.4%) and MRI (sensitivity 83.8%, specificity 83.1%) with no statistically significant difference observed. Therefore, the choice between ultrasound and MRI should depend primarily on availability and the skill of the operator.<sup>20</sup> Of 5,219 patients, 181 (3.5%) were predicted to have PAS based on ultrasound (US) scanning. Ultrasonography had 100% sensitivity and 99.9% specificity for detecting severe PAS (placenta increta and percreta). For all PAS types, however, the sensitivity dropped to 25.8% with high specificity still at 99.8%. Ultrasound imaging and MRI showed concordance in 78.5% of severe cases; however, for cases of placenta accreta, the concordance was only 20%.<sup>11</sup>

In our study of 43 cases of Placenta Accreta Spectrum (PAS), it was noted that ultrasound was more sensitive and specific than MRI (ultrasound: 86% sensitivity, 50% specificity; MRI: 76% sensitivity, 40% specificity). However, when MRI was performed with structured reporting that included detailed assessment of the extent of involvement of Placenta Percreta, its diagnostic performance approached that of ultrasound.<sup>21</sup> It is important to note that while ultrasound is a key diagnostic tool for PAS, the absence of sonographic features does not exclude the diagnosis. Other modalities, such as MRI, serology, and histopathology are vital for the diagnosis.<sup>2</sup>

PAS predictors were prior cesareans, smoking, loss of the retroplacental clear space, myometrial thinning, placental lacunae, intraplacental dark bands (IDB), focal myometrial border interruption (FIMB), and abnormal vascularity. MRI was the most accurate tool (AUC 0.94-0.97). It was better than the

ultrasound and clinical risk factors (CRF). In the multivariable analysis, only IDB and FIMB were independent predictors. As a practical strategy, use CRF and ultrasound first, and keep MRI for cases that remain ambiguous.<sup>22</sup> In a cohort of 299 patients with major placenta previa, 91 (30.5%) had confirmed PAS. Advanced maternal age, higher parity, and an increased number of cesarean deliveries, including repeated cesareans at advanced age, were identified as significant risk factors for PAS. The majority of PAS cases were accurately identified through ultrasound evaluation.<sup>23</sup>

In our study, we demonstrated the diagnostic accuracy of ultrasound in the diagnosis of PAS with complete evidence. It includes all the comprehensive subgroup analysis in all the recent studies available.

## CONCLUSION:

According to the research findings, ultrasonography is sensitive and accurate modality for detection of placenta accreta. It has significantly enhanced capacity to identify the condition and enhances patient care by enabling us to make the right pre-operative management decisions. Therefore, in order to lower maternal morbidity and death, we advise using ultrasonography as the primary screening tool due to its non-invasive nature and high sensitivity for accurate detection of placenta accreta in high-risk individuals.

## LIMITATIONS:

This study has certain limitations. Being a single-center study, the generalizability of findings may be limited. Ultrasonography is operator-dependent, which may influence diagnostic performance. Intraoperative findings were used as the reference standard rather than histopathological confirmation in all cases.

REFERENCE:

1. Jauniaux E, Bunce C, Grønbeck L, Langhoff-Roos J. Prevalence and main outcomes of placenta accreta spectrum: a systematic review and meta-analysis. *Am J Obstet Gynecol.* 2019;221(3):208–218. doi:10.1016/j.ajog.2019.01.233
2. Arakaza A, Zou L, Zhu J. Placenta accreta spectrum diagnosis challenges and controversies in current obstetrics: a review. *Int J Womens Health.* 2023;15:635–654. doi:10.2147/IJWH.S395271
3. Takeda S, Takeda J, Makino S. Cesarean section for placenta previa and placenta previa accreta spectrum. *Surg J.* 2020;6(Suppl 2):S110–S121. doi:10.1055/s-0039-3402036
4. Bostancı E, Kılıcı C, Özkaya E, Yayla CA, Darıcı E, Berkel G, et al. Ultrasound predictors of candidates for segmental resection in pregnant women with placenta accreta. *J Matern Fetal Neonatal Med.* 2020;33(6):1004–1007. doi:10.1080/14767058.2018.1514377
5. Del Negro V, Aleksa N, Galli C, Ciminello E, Derme M, Vena F, et al. Ultrasonographic diagnosis of placenta accreta spectrum disorder: ideation of an ultrasonographic score and correlation with surgical and neonatal outcomes. *Diagnostics (Basel).* 2021;11(1):23. doi:10.3390/diagnostics11010023
6. Jauniaux E, Ayres-de-Campos D, FIGO Placenta Accreta Diagnosis and Management Expert Consensus Panel. FIGO consensus guidelines on placenta accreta spectrum disorders: epidemiology. *Int J Gynecol Obstet.* 2018;140(3):265–273. doi:10.1002/ijgo.12407
7. Chen L, Shi HF, Jiang H, Shi XM, Wang YY, Zhang AQ, et al. Correlation of an ultrasonic scoring system and intraoperative blood loss in placenta accreta spectrum disorders: a retrospective cohort study. *Biomed Environ Sci.* 2021;34(2):163–169. doi:10.3967/bes2021.022
8. Maged AM, El-Mazny A, Kamal N, Mahmoud SI, Fouad M, El-Nassery N, et al. Diagnostic accuracy of ultrasound in the diagnosis of placenta accreta spectrum: systematic review and meta-analysis. *BMC Pregnancy Childbirth.* 2023;23:354. doi:10.1186/s12884-023-05675-6
9. Ghezzi CLA, Silva CK, Casagrande AS, Westphalen SS, Salazar CC, Vettorazzi J. Diagnostic performance of radiologists with different levels of experience in the interpretation of MRI of placenta accreta spectrum disorder. *Br J Radiol.* 2021;94(1128):20210827. doi:10.1259/bjr.20210827
10. Amirabi A, Amjadipour N, Dinparast L. Diagnostic value of Doppler ultrasonography in the diagnosis of morbidly adherent placenta. *J Obstet Gynecol Cancer Res.* 2018;3(1):23–27. doi:10.21859/joqcr.3.1.23
11. Baumann HE, Pawlik LKA, Hoesli I, Schoetzau A, Schoenberger H, Butenschoen A, et al. Accuracy of ultrasound for the detection of placenta accreta spectrum in a universal screening population. *Int J Gynecol Obstet.* 2023;161(3):920–926. doi:10.1002/ijgo.14595
12. Liu Y, Gao X, Shi D, Wang Y, Qi X, Wang N. Changes of placental three-dimensional power Doppler ultrasonography in third trimester among hypertensive disorders complicating pregnancy. *Biomol Biomed.* 2023;23(5):894–901. doi:10.17305/bb.2023.9085
13. Agarwal S, Agarwal A, Chandak S. Role of placenta accreta index in prediction of morbidly adherent placenta: a reliability study. *Ultrasound J.* 2021;29(2):92–99. doi:10.1177/1742271X20959742
14. Juan-Clar M, Torrent M, Santandreu P, Arejola E, Ibarra J, Tubau A. Effectiveness of ultrasound screening for placenta accreta spectrum using standard ultrasound criteria in a secondary care setting. *Fetal Diagn Ther.* 2022;49(1-2):52–59. doi:10.1159/000521738



15. Coutinho CM, Giorgione V, Noel L, Liu B, Chandraharan E, Pryce J, et al. Effectiveness of contingent screening for placenta accreta spectrum disorders based on persistent low-lying placenta and previous uterine surgery. *Ultrasound Obstet Gynecol.* 2021;57(1):91-96. doi:10.1002/uog.23100
16. Hong S, Le Y, Lio KU, Zhang T, Zhang Y, Zhang N. Performance comparison of ultrasonography and magnetic resonance imaging in diagnostic accuracy of placenta accreta spectrum disorders: a systematic review and meta-analysis. *Insights Imaging.* 2022;13(1):1-13. doi:10.1186/s13244-022-01192-w
17. Najeeb S, Samina, Mumtaz N, Gul Y, Sadaf R, Naeem A. Diagnostic precision of color Doppler ultrasound for antenatal diagnosis of placenta accreta compared to histopathology in obstetric practice. *Ann Punjab Med Coll.* 2022;16(4):375-378. doi:10.29054/apmc/2022.1154
18. Movahedi M, Farahbod F, Mootamedi M. Evaluation and comparison of sensitivity and specificity of ultrasonography in placenta accreta diagnosis in the second and third trimesters. *Adv Biomed Res.* 2023;12:188. doi:10.4103/abr.abr\_188\_22
19. Alalfy M, Hamed ST, Ghani ASAE, Elgazzar A, Abbassy A, Rashwan ASSA, et al. Accuracy of 3D-TUI and 3D power Doppler using Alalfy criteria in diagnosis of placenta accreta spectrum. *Clin Exp Obstet Gynecol.* 2021;48(5):1132-1140. doi:10.31083/j.ceog4805182
20. De Oliveira Carniello M, Oliveira Brito LG, Sarian LO, Bennini JR. Diagnosis of placenta accreta spectrum in high-risk women using ultrasonography or magnetic resonance imaging: systematic review and meta-analysis. *Ultrasound Obstet Gynecol.* 2022;59(4):428-436. doi:10.1002/uog.24861
21. Raj G, Raj R. Comparative analysis of ultrasound and MRI in diagnosis of placenta accreta spectrum. *Ultrasound Obstet Gynecol.* 2024;64(S1):257. doi:10.1002/uog.28634
22. Romeo V, Verde F, Sarno L, Migliorini S, Petretta M, Mainenti PP, et al. Prediction of placenta accreta spectrum in patients with placenta previa using clinical risk factors, ultrasound and MRI findings. *Radiol Med.* 2021;126(9):1216-1225. doi:10.1007/s11547-021-01348-6
23. Shaamash AH, AlQasem MH, Al GDS, Mahfouz AA, Eskandar MA. Adjunctive MRI in diagnosis of placenta accreta spectrum in major placenta previa: incidence, risk factors and maternal morbidity. *Ann Saudi Med.* 2023;43(4):219-226. doi:10.5144/0256-4947.2023.219

