

## ULTRASONIC ASSESSMENT OF EXTENSOR, FLEXOR, INTRINSIC THENAR MUSCLES GROUP AND NERVES OF WRIST JOINT IN PATIENTS OF HYPOTHYROIDISM

Ukasha Qamar<sup>1</sup>, Laraib Fatima<sup>2</sup>, Ahmad Mehmood<sup>3</sup>, Khalid Nazir<sup>4</sup>, Rimsha Iftikhar<sup>5</sup>, Hira Azmat<sup>6</sup>, Umer Nazir<sup>7</sup>

<sup>1,2</sup>Department of Medical Imaging Technology, Faculty of Allied Health Sciences, The Superior University, Pakistan

<sup>3,4</sup>University Institute of Radiological Sciences & Imaging Technology (UIRSMIT), Faculty of Allied Health Sciences, The University of Lahore, Pakistan

<sup>5</sup>Department of Radiology, Cancer Care Hospital & Research Center Lahore, Pakistan

<sup>6</sup>Faculty of Allied Health Sciences, The Superior University, Pakistan

<sup>7</sup>University Institute of Radiological Sciences & Imaging Technology (UIRSMIT), Faculty of Allied Health Sciences, The University of Lahore, Pakistan

<sup>1</sup>ukashaqamar0@gmail.com, <sup>2</sup>laraib.shan@yahoo.com, <sup>3</sup>ahmadmehmoodps@gmail.com, <sup>4</sup>shaheerhashir9@gmail.com, <sup>5</sup>juttrimsha222@gmail.com, <sup>6</sup>hiraazmat0569@gmail.com, <sup>7</sup>jellahaumer786@gmail.com

DOI: <http://doi.org/10.5281/zenodo.20320876>

### Keywords

Musculoskeletal Ultrasound (MSUS), Cross Sectional Area (CSA), Carpal Tunnel Syndrome (CTS), Subclinical Hypothyroidism (SCH)

### Article History

Received: 25 March 2026

Accepted: 05 May 2026

Published: 20 May 2026

Copyright @Author

Corresponding Author: \*

Ahmad Mehmood

### Abstract

**Introduction:** Hypothyroidism is a common endocrine disorder associated with a wide range of musculoskeletal and neuromuscular complications, particularly involving the wrist and hand. Conditions such as CTS, tendon abnormalities and muscle atrophy are frequently reported but often remain underdiagnosed. MSUS has emerged as noninvasive, cost effective and dynamic imaging modality that allows real time assessment of muscles, tendons, joints and nerves.

**Aim of the study:** This study aims to assess the role of MSUS in evaluating extensor, flexor and intrinsic thenar muscle groups, nerves changes in patients with hypothyroidism and to compare these findings with healthy controls.

**Methodology:** A comparative cross-sectional study will be conducted over a period of 4 months at NIH&RC. A total sample consisting of hypothyroid patients (GROUP A) and healthy controls (GROUP B) will be included. Age participants aged 18-60 years clinically and biochemically confirmed hypothyroidism will be selected based on inclusion and exclusion criteria. High frequency ultrasound (7-15 MHz linear probe) will be used to assess muscle thickness, echotexture and contractility, along wrist joint features such as effusion, synovial hypertrophy and tendon abnormalities. Median nerve cross sectional area (CSA) at the carpal tunnel inlet will also be measured. Data will be analyzed using SPSS, applying appropriate statistical tests with a significant level of  $p < 0.05$ .

**Results:** A total of 64 participants were included, comprising both hypothyroid patients and healthy controls. Most participants were female (62.5%) and belonged to the 21-40 years' age group. Right-sided involvement was most common, and most patients reported symptoms lasting more than 3 months. On

ultrasound, swelling was the most frequent finding ( $n = 50$ ), while synovial thickening ( $n = 14$ ) and increased vascularity ( $n = 4$ ) were less common. Clinically, wrist pain, numbness, and tenderness were reported in a smaller proportion of participants, while effusion and trauma history were rare. Statistical analysis showed a significant difference in swelling between groups ( $t = 4.91, p < .001$ ), confirming higher swelling in the affected group.

**Conclusion:** This study concludes that hypothyroidism significantly affects wrist joint structures, including muscles, tendons, and the median nerve, leading to conditions such as CTS. MSUS is an effective, non-invasive imaging modality for early detection. Its use can improve diagnosis, guide management, and reduce complications in hypothyroid patients.

## INTRODUCTION

Thyroid gland dysfunction is a major global health concern, with the two principal disorders being hypothyroidism and hyperthyroidism. These conditions arise due to an imbalance in thyroid hormone production, either deficiency or excess, and they exert widespread systemic effects on multiple organ systems. Thyroid diseases affect approximately 1.6 billion individuals worldwide. In Pakistan, thyroid disorders represent a considerable public health burden. The prevalence of hypothyroidism has been reported to be 4.1%. SCH affects approximately 5.4% of the population. Similarly, hyperthyroidism has a prevalence of 5.1%, and subclinical hyperthyroidism accounts for about 5.8% (1). SCH is defined by elevated thyroid-stimulating hormone (TSH) levels with normal circulating thyroid hormone levels. Patients with SCH, particularly those with TSH levels greater than 10 mIU/L, are at increased risk of progression to overt hypothyroidism (2).

In addition, thyroid-related musculoskeletal issues are prevalent, research has traditionally concentrated on median nerve involvement, leaving a significant gap in the combined assessment of wrist muscles and joint pathologies such as tendon changes, synovial thickening, and joint effusions in hypothyroid patients. Furthermore, CTS (CTS) has been found to be significantly more common in hypothyroid patients, with statistical analysis showing a strong association between thyroid dysfunction and CTS ( $P = 0.004$ ) (3).

Endocrine disorders frequently produce characteristic changes in the hand and wrist due to their systemic impact on connective tissue and neuromuscular structures. Thyroid dysfunction, in particular, leads to alterations in tissue metabolism, resulting in stiffness, swelling, and impaired function of joints and tendons. These changes are often subtle initially but can progress to significant disability if left untreated (4).

These statistics highlight the widespread nature of thyroid dysfunction in the region and underscore the importance of early detection and management strategies. Understanding the global frequency and incidence of both hypothyroidism and hyperthyroidism is essential for developing effective healthcare policies and interventions (5). Early evaluation using musculoskeletal ultrasound (MSUS) offers a non-invasive and cost-effective pathway for timely treatment, potentially improving patient quality of life and reducing the necessity for surgical intervention. The overall prevalence of hypothyroidism worldwide has been estimated at 10.95%, with 3.47% of cases previously undiagnosed and 7.48% self-reported by patients (6).

Thyroid dysfunction has a profound impact on the musculoskeletal system. In a study evaluating individuals with varying degrees of thyroid function, the frequency of these musculoskeletal conditions was assessed, demonstrating a clear association between thyroid disease and musculoskeletal complications (3).

Clinical observations indicate that many patients with hypothyroidism present late with

musculoskeletal complaints. Approximately 90.3% of patients visited rheumatology clinics three years after being diagnosed with hypothyroidism, while 7.5% presented within one year, and only 2.2% presented ten years after diagnosis (7).

Neuromuscular involvement is a significant feature of hypothyroidism. Studies have reported that 38% of hypothyroid patients exhibit clinical muscle weakness as measured by manual muscle strength testing. CTS is present in 29% of these patients, while 42% demonstrate features of sensorimotor axonal neuropathy (8).

The clinical evaluation of CTS involves a series of well-established diagnostic tests. These include the manual compression test, Phalen's test, and Tinel's sign at the wrist, which are used to assess median nerve compression (9). Laboratory investigations are essential for the diagnosis and management of thyroid disorders. Blood tests commonly performed include measurement of thyroid-stimulating hormone (TSH), free thyroxine (FT4), and free triiodothyronine (FT3) (10).

By comparatively assessing both muscle and joint pathologies, this study aims to bridge this critical diagnostic gap, providing a more comprehensive understanding of the systemic impact of thyroid dysfunction on the wrist joint and its surrounding soft tissue structures. Imaging techniques play an important role in evaluating musculoskeletal complications associated with thyroid dysfunction. Compared to other imaging modalities such as computed tomography (CT) and magnetic resonance imaging (MRI), ultrasound (US) offers several advantages. MSUS allows simultaneous scanning of multiple anatomical structures, provides dynamic imaging of target areas, and enables real-time assessment by the clinician. (11).

Peripheral nerve involvement is a well-recognized complication of hypothyroidism. CTS, the most common entrapment neuropathy of the upper limb, results from compression of the median nerve at the wrist. This compression leads to an increase in the median nerve cross-sectional area (CSA), which can be detected using imaging techniques such as ultrasound (12). CTS is the most prevalent entrapment neuropathy and

represents a significant clinical concern in patients with thyroid dysfunction. Studies evaluating its use in different populations, including the Saudi population, have demonstrated its validity and accuracy in diagnosing CTS (13).

## METHODOLOGY

This comparative cross-sectional study was conducted over a period of 4 months at the Novocare International Hospital & Research Center (NIH&RC).

A total sample size of 64 participants was recruited and divided equally into two distinct cohorts: Group A, consisting of 32 adult patients with clinically and biochemically confirmed hypothyroidism, and Group B, serving as a control group with 32 age- and gender-matched healthy individuals who had no prior history of thyroid or systemic musculoskeletal disorders.

To maintain diagnostic precision, strict selection criteria were applied; inclusion required a proven abnormal thyroid profile (TSH, T3, T4 levels) alongside formal informed consent, while patients with confounding systemic conditions capable of causing peripheral neuropathies or joint disease, such as Diabetes Mellitus, Rheumatoid Arthritis, or Lupus, were strictly excluded from the study.

Prior to the sonographic assessments, all participants underwent standardized clinical provocative screenings, including Phalen's flexion test, where the wrists were maintained in complete flexion for 40 to 60 seconds to detect localized numbness or tingling along the median nerve path and a percussion test applied systematically along the course of the median nerve.

The primary diagnostic evaluation was carried out via high-frequency musculoskeletal ultrasound (MSUS) utilizing a linear transducer operating at a high-resolution bandwidth of 7–15 MHz. The ultrasound protocol focused on measuring the precise cross-sectional area (CSA) of the median nerve at the carpal tunnel inlet, while simultaneously assessing the structural thickness, architectural echotexture, and real-time dynamic contractility of the extensor, flexor, and intrinsic thenar muscle groups, along with monitoring the joint spaces for signs of effusion or synovial thickening. All gathered data were compiled,

processed, and statistically evaluated through SPSS software, utilizing independent sample t-tests to identify significant structural variations

between the two groups, with the significance threshold rigidly defined at a p-value of less than 0.05.

## RESULTS

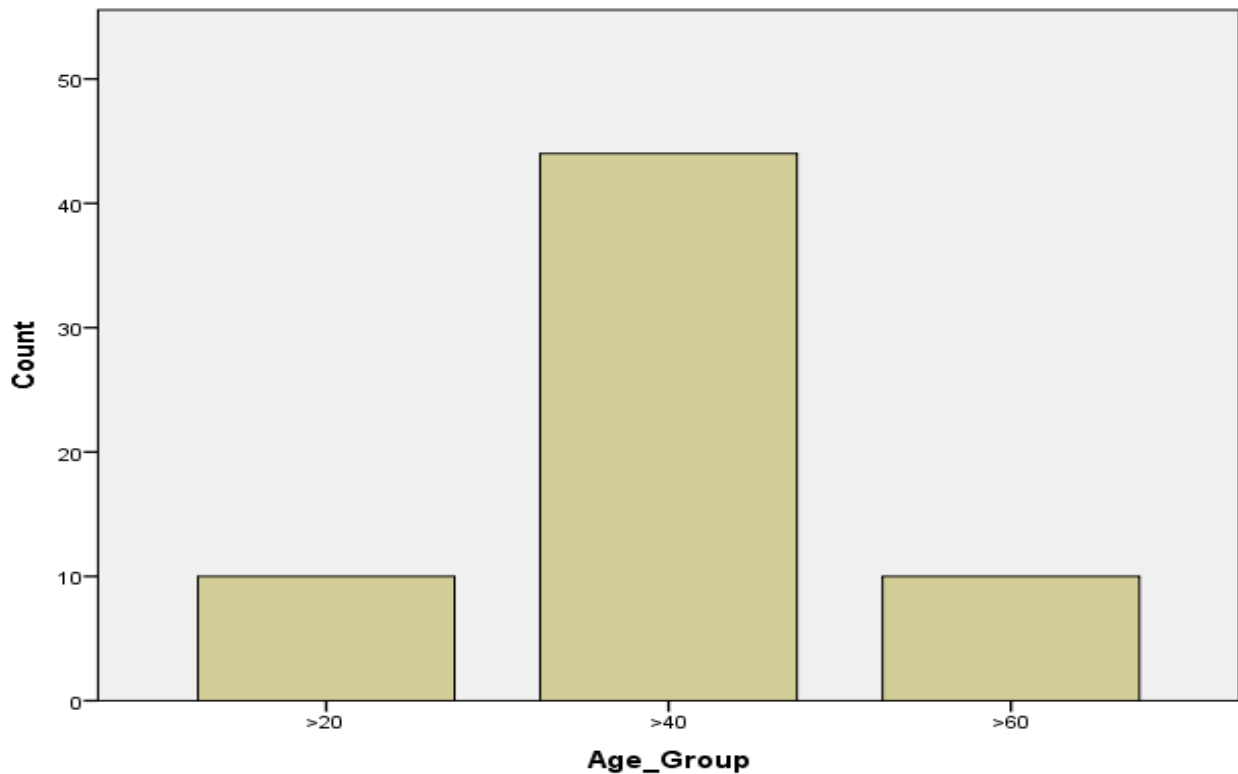


Figure 4.1: Table represent age distribution of the study participants

This indicates a sample heavily weighted toward the middle category, which contains over **two-thirds** of the total population represented. (>20)

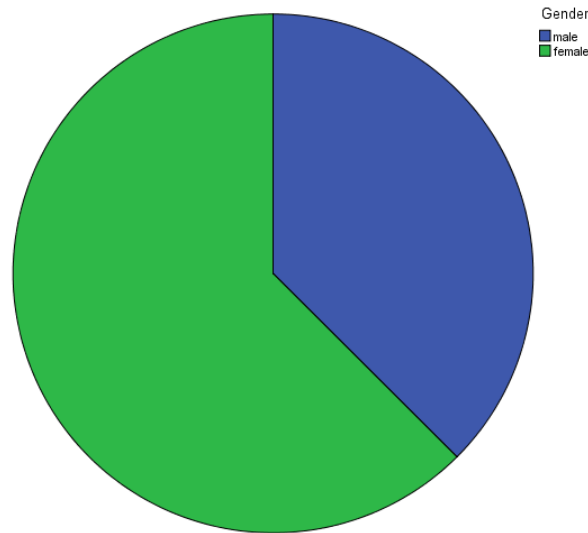


Figure4.2: Pie chart shows gender Distribution

The data indicates a female-majority demographic, with women making up 63% of the total group. Males, represented by the blue section, account for 37% of the population.

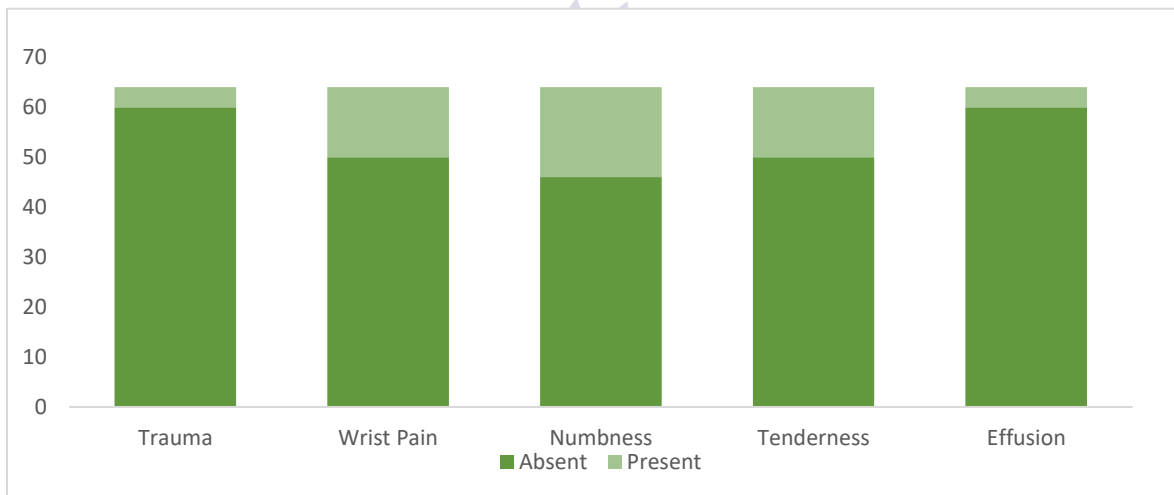


Fig 4.3: Table represent frequency of clinical symptoms

Overall, most symptoms are more commonly absent than present. Trauma and effusion, in particular, are largely absent, suggesting they occur less frequently in this population. In contrast,

wrist pain and tenderness appear more often and show a relatively higher rate of presence compared to the other features, making them more commonly reported complaints.

Table 4.1: Table represent Synovial Thickening cross tabulation with Hypothyroidism

Synovial Thickening Cross tabulation			
	Syn Thickening		Total
	normal	increase	

Hypothyroidism	22	10	32
Normal	32	0	32
Total	54	10	64

The cross tabulation shows that **10 participants** in the hypothyroid group exhibited increased synovial thickening, while **none** was found in the

healthy group. This indicates that roughly **31%** of hypothyroid patients presented with this specific joint pathology.

**Table 4.2:** Table represent the mean swelling value

	Group	N	Mean	Std. Deviation	Std. Error Mean
Swelling	hypothyroidism	32	.44	.504	.089
	normal	32	.00	.000	.000

Hypothyroid patients showed measurable swelling (mean = 0.44), while controls had no swelling, indicating a clear group difference.

**Table 4.3:** Table represent Vascularity Crosstabulation with hypothyroidism

Vascularity Crosstabulation			
	Vascularity		Total
	normal	increased	
hypothyroidism	28	4	32
normal	32	0	32
Total	60	4	64

The Crosstabulation reveals that **4 hypothyroid participants** showed increased vascularity, while **none** was found in the normal group.

**Table 4.4:** Table represent the mean effusion value

Group Statistics					
	Group	N	Mean	Std. Deviation	Std. Error Mean
Effusion	hypothyroidism	32	.13	.336	.059
	normal	32	.00	.000	.000

The **hypothyroid group** (M=0.13) exhibits measurable joint effusion, **control group** (M=0.00) shows no fluid accumulation

**Table 4.4:** Table represent thenar muscle Bulk Crosstabulation with hypothyridism

Group Thenar muscle Bulk Crosstabulation			
	Thenar muscle Bulk		Total
	normal	enlarge	
hypothyroidism	22	10	32
normal	32	0	32

Total	54	10	64
-------	----	----	----

This crosstabulation reveals that 31.2% (10 out of 32) of hypothyroid patient’s exhibit enlarged thenar muscle bulk, whereas the control group shows 0% abnormalities. All 32 healthy subjects maintained normal muscle bulk, highlighting a clear distinction between the two groups.

Figure 4.4: The bar chart shows that the mean ROM score in hypothyroid patients

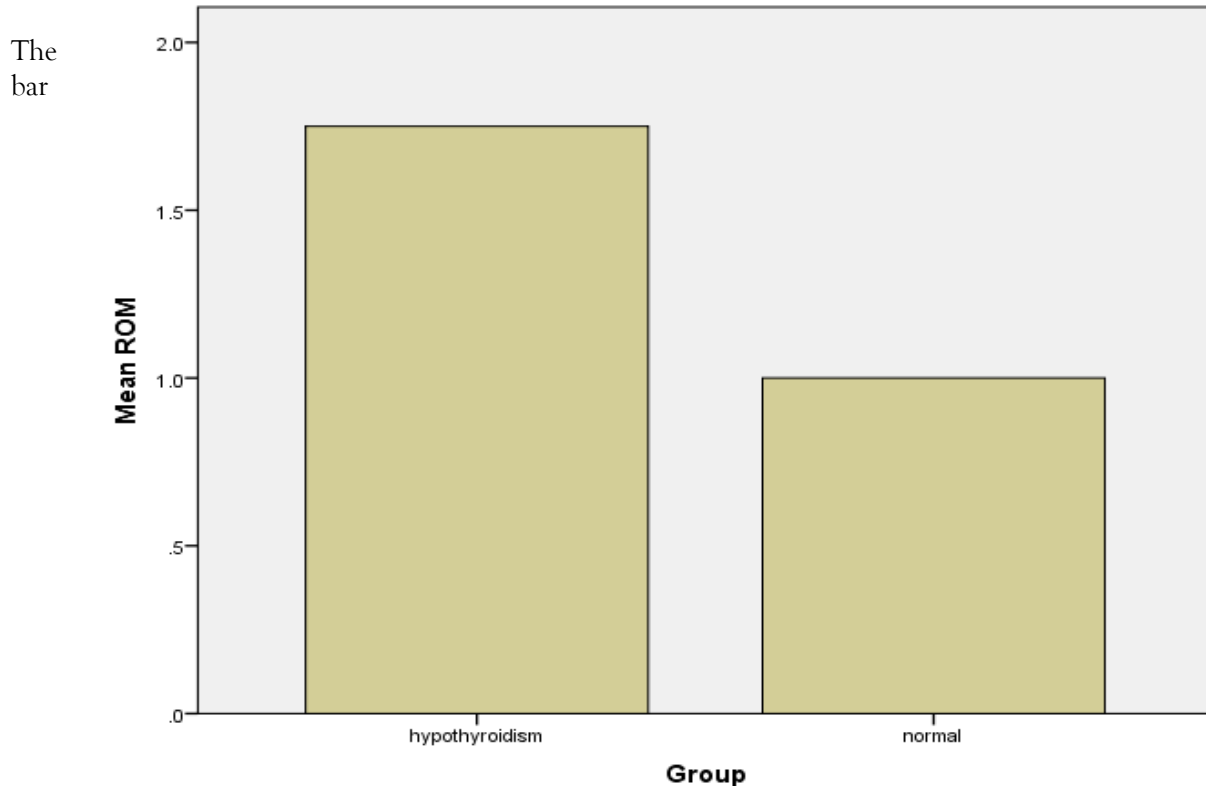


chart shows that the mean ROM score in hypothyroid patients is higher (closer to 2), indicating reduced range of motion, while the normal group has a mean closer to 1, representing normal ROM. A higher proportion of hypothyroid patients showed reduced ROM compared to normal individuals.

**DISCUSSION**

This study focused on the force exerted by the transducer during an ultrasound examination. The findings showed that applied force could influence diagnostic parameters, such as the flattening ratio. However, area measurements remained largely unchanged despite the force

applied, indicating that volume measurements derived from 3-D models would not be significantly affected. The experimental investigations also identified a relationship between computer use and reduced nerve functionality. This was important not only for understanding the development of CTS but also for highlighting the potential for misdiagnosis. Furthermore, the new sonographic techniques introduced in this study demonstrated strong potential for diagnosing CTS while addressing the issue of false diagnoses commonly associated with NCS (14).

This study focused on the force exerted by the transducer during an ultrasound examination.

The findings showed that applied force could influence diagnostic parameters, such as the flattening ratio. However, area measurements remained largely unchanged despite the force applied, indicating that volume measurements derived from 3-D models would not be significantly affected. The experimental investigations also identified a relationship between computer use and reduced nerve functionality. This was important not only for understanding the development of CTS but also for highlighting the potential for misdiagnosis. Furthermore, the new sonographic techniques introduced in this study demonstrated strong potential for diagnosing CTS while addressing the issue of false diagnoses commonly associated with NCS (15).

CTS develops in three stages, with signs and symptoms varying according to severity. Although symptom provocation during diagnostic tests may suggest median nerve compression in the carpal tunnel, further investigations are necessary for accurate diagnosis. The study found that both neurodynamics combined with general exercises and general exercises alone reduced pain and disability in CTS patients. However, neurodynamics with exercises showed comparatively better overall outcomes in reducing NPRS scores after treatment and at the two-week follow-up (16).

The ability of MSUS to provide real time, dynamic imaging makes it highly valuable for early detection and monitoring of such conditions. The use of clinical tests such as Phalen's test and percussion in this study also demonstrated their relevance in identifying CTS. Previous researches has shown a significant association between positive Phalen's test and hypothyroidism (17).

## CONCLUSION

In conclusion, this comparative cross-sectional study demonstrates that primary and subclinical hypothyroidism induce significant, measurable alterations in the soft tissues, musculature, and neural pathways of the wrist joint. High-frequency musculoskeletal ultrasound (MSUS) successfully verified that passive mechanical compression, driven by metabolic mucopolysaccharides

accumulation and my edematous interstitial fluid retention, serves as the dominant pathogenetic mechanism behind wrist abnormalities in these patients, rather than active hyper vascular inflammation. This structural burden was mathematically validated by the highly significant disparity in localized tissue swelling and edema observed between the hypothyroid cohort and the healthy controls ( $t = 4.91$ ,  $p < 0.001$ ). While traditional diagnostic clinical paths rely heavily on manual provocative clinical tests or invasive nerve conduction studies (NCS) that lack physical cross-sectional visualization, high-resolution MSUS operating at 7-15 MHz offers an excellent, rapid, and objective scanning tool. This early diagnostic approach optimizes medical management strategies, tracks treatment response following thyroxine replacement therapies, and drastically reduces the need for late-stage surgical decompression releases, thereby significantly preserving upper extremity functional capacity and improving overall patient quality of life.

## Limitations:

Small sample size (n=64).

Cross-sectional design prevents long-term outcome tracking.

US is operator-dependent.

## Recommendations include:

Routine MSK screening should be considered in hypothyroid patients presenting with wrist or hand symptoms.

Early diagnosis and timely management of CTS should be prioritized to prevent permanent nerve damage.

Clinicians should adopt an integrated approach, combining clinical examination, laboratory tests, and imaging for accurate diagnosis.

Further studies with larger sample sizes are recommended to validate these findings.

Longitudinal research should be conducted to assess the effect of thyroid hormone replacement therapy on musculoskeletal changes

## REFERENCES

- Shah N, Ursani TJ, Shah NA, Raza HMZ. 3. Prevalence and etiology of thyroid disease: A review. *Pure and Applied Biology (PAB)*. 2021;10(3):691-702.
- Rosário PW, Bessa B, Valadao MM, Purisch S. Natural history of mild SCH: prognostic value of ultrasound. *Thyroid*. 2009;19(1):9-12.
- Cakir M, Samanci N, Balci N, Balci MK. Musculoskeletal manifestations in patients with thyroid disease. *Clinical endocrinology*. 2003;59(2):162-7.
- Scullion S, Grainger AJ, Greenspan A, editors. *Radiologic imaging of metabolic and endocrine disorders as they affect the hand and wrist*. Seminars in Musculoskeletal Radiology; 2021: Thieme Medical Publishers, Inc.
- Unnikrishnan AG, Kalra S, Sahay RK, Bantwal G, John M, Tewari N. Prevalence of hypothyroidism in adults: An epidemiological study in eight cities of India. *Indian journal of endocrinology and metabolism*. 2013;17(4):647-52.
- Olatunde Odusan M, FMCP DAA. Spectrum of Rheumatology Disorders among Patients Presenting with Hypothyroidism. 2020.
- Duyff RF, Van den Bosch J, Laman DM, van Loon B-JP, Linssen WH. Neuromuscular findings in thyroid dysfunction: a prospective clinical and electrodiagnostic study. *Journal of Neurology, Neurosurgery & Psychiatry*. 2000;68(6):750-5.
- Palumbo CF, Szabo RM, Olmsted SL. The effects of hypothyroidism and thyroid replacement on the development of CTS. *The Journal of hand surgery*. 2000;25(4):734-9.
- Soh S-B, Aw T-C. Laboratory testing in thyroid conditions-pitfalls and clinical utility. *Annals of laboratory medicine*. 2019;39(1).
- Dinescu SC, Ionescu RA, Popoviciu HV, Avram C, Vreju FA. Musculoskeletal and Nerve. *Ultrasound Imaging: Current Topics*. 2022:55.
- Singh k, gupta k, kaur i, arora v. Role of high-resolution ultrasonography in evaluation of median nerve and thickness of flexor retinaculum in patients with hypothyroidism. *Indian journal of musculoskeletal radiology* **учредители: scientific scholar**. 2020;2:36-43.
- Elnady B, Rageh EM, Ekhouly T, Fathy SM, Alshaar M, Fouda ES, et al. Diagnostic potential of ultrasound in CTS with different etiologies: correlation of sonographic median nerve measures with electrodiagnostic severity. *BMC musculoskeletal disorders*. 2019;20(1):634.
- Radu I, Groppa L, Vudu L. Musculoskeletal impairment in primary hypothyroidism. *The Medical-Surgical Journal*. 2016(2):244-51.
- Donoghue MF. *The variation of median nerve functionality with wrist postures typical of computer use and a novel ultrasound technique for the diagnosis of carpal tunnel syndrome* (Doctoral dissertation).
- Picasso R. *Frontiers in High-resolution ultrasound imaging: unlock the potential of Ultrasound in providing quantitative biomarkers in Musculoskeletal Radiology (ENHANCE-US)*.
- Aditi K, Manish JK, Vaibhav A, Yadav N. Analysing the Effects of Neuro-dynamics in Carpal Tunnel Syndrome in Pain and Disability: A Randomized Control Trial.
- El-Hadidi KT, Mansour MA, El-Wakd MM, El-Emary AE. Thyroid dysfunction and anti-thyroid antibodies in Egyptian patients with systemic lupus erythematosus: Correlation with clinical musculoskeletal manifestations. *The Egyptian Rheumatologist*. 2014;36(4):173-8.