

DIAGNOSTIC ACCURACY OF TRIPHASIC CT VERSUS ULTRASONOGRAPHY IN DETECTING LIVER LESIONS IN DIABETIC PATIENTS: A PILOT CASE SERIES

¹Ansa Farooq, ²Nida Parveen, ³Marwa Ishfaq, ⁴Bushra, ⁵Gulshah, ⁶Zaryab Khan

¹Student, Faculty of Allied Health Sciences, The Superior University Lahore, Sargodha Campus

²Student, Faculty of Allied Health Sciences, The Superior University Lahore, Sargodha Campus

³Student, Faculty of Allied Health Sciences, The Superior University Lahore, Sargodha Campus

⁴Student, Faculty of Allied Health Sciences, The Superior University Lahore, Sargodha Campus

⁵Student, Faculty of Allied Health Sciences, The Superior University Lahore, Sargodha Campus

⁶Lecturer, Faculty of Allied Health Sciences, The Superior University Lahore, Sargodha Campus

ORCID: [0009-0009-6772-1957](https://orcid.org/0009-0009-6772-1957)

[*zaryabbakhar@gmail.com](mailto:zaryabbakhar@gmail.com)

DOI: <https://doi.org/10.5281/zenodo.20773945>

Keywords

Diabetes mellitus, Liver lesions, Hepatocellular carcinoma, Triphasic CT, Ultrasonography, Diagnostic accuracy, NAFLD.

Article History

Received on 22 May 2026

Accepted on 19 June 2026

Published on 20 June 2026

Copyright @Author

Corresponding Author: *

Ansa Farooq

Abstract

Background: Diabetes mellitus is increasingly associated with hepatic complications, including NAFLD, cirrhosis, and hepatocellular carcinoma (HCC). Liver lesions in diabetic patients may remain clinically silent, making imaging essential for early detection. Although abdominal ultrasound (USG) is commonly used as the initial imaging modality due to its availability and safety, its accuracy may decrease in patients with fatty liver and chronic liver disease. Triphasic computed tomography (CT) provides improved lesion detection and characterization through multiphase contrast enhancement but involves higher cost, radiation exposure, and contrast-related risks. Objective: This study aimed to compare the diagnostic performance of abdominal ultrasound and triphasic CT for detection and characterization of liver lesions in diabetic patients and to evaluate the ability of ultrasound to identify lesions detected by CT. Methods: This prospective pilot diagnostic accuracy case series included 5 male patients with type 2 diabetes mellitus and suspected liver lesions. All participants underwent abdominal ultrasound and triphasic CT within two weeks. Ultrasound was considered the index test, while triphasic CT was used as the reference standard because histopathological confirmation was unavailable. Clinical parameters, including HbA1c, liver function tests, and imaging findings, were recorded. Ultrasound sensitivity and accuracy were calculated using CT findings as the reference. Results: The five patients had a mean age of 57.8 years (range: 36–68 years) and a mean HbA1c level of 8.9%. Triphasic CT detected and characterized all lesions, achieving 100% sensitivity. Ultrasound detected lesions in four out of five patients, resulting in a sensitivity and accuracy of 80%. The single false-negative case occurred in a 65-year-old patient with poor glycemic control (HbA1c 11.2%) and chronic liver disease, where ultrasound missed a large 9.3 cm HCC and reported only a small 13 mm echogenic lesion suggestive of hemangioma. Ultrasound also showed limitations in lesion characterization, including misclassification of malignant lesions as benign lesions. Conclusion: Triphasic CT demonstrated superior diagnostic performance compared with abdominal ultrasound for detecting and characterizing liver lesions in diabetic patients, particularly those with poor glycemic control and chronic liver disease. Ultrasound remains useful as an accessible screening tool; however, it may not be sufficient as the sole imaging modality in high-risk diabetic patients. Larger multicenter studies with histopathological confirmation are required to establish definitive imaging protocols.

INTRODUCTION

Diabetes mellitus has become one of the major global health challenges, with approximately 537 million adults affected worldwide in 2021, a number projected to increase to 783 million by 2045 [1, 2]. Type 2 diabetes accounts for more than 90% of all diabetes cases [2]. Low- and middle-income countries, including Pakistan, face a substantial burden, with nearly 33 million adults currently living with diabetes [16]. Although diabetic complications such as nephropathy, neuropathy, retinopathy, and cardiovascular disease are well recognized [28], the association between diabetes and liver disease is receiving increasing attention. Diabetes significantly increases the risk of hepatic abnormalities ranging from fatty liver disease to cirrhosis and hepatocellular carcinoma (HCC) [1, 4, 6].

Diabetic patients have a two- to three-fold higher risk of developing liver lesions compared with non-diabetic individuals [18, 23]. These lesions may be benign, including hemangiomas, focal nodular hyperplasia, and abscesses, or malignant, such as HCC and metastatic tumors. The relationship between diabetes and liver lesions involves multiple mechanisms, including chronic hyperglycemia, insulin resistance, oxidative stress, and systemic inflammation. These factors promote hepatic fat accumulation, leading to non-alcoholic fatty liver disease (NAFLD), which affects up to 70% of individuals with type 2 diabetes [4, 30, 33]. Progressive NAFLD may develop into non-alcoholic steatohepatitis (NASH), fibrosis, cirrhosis, and eventually HCC, even in the absence of viral hepatitis [5, 6, 13].

Hyperglycemia promotes the formation of advanced glycation end products (AGEs), which activate inflammatory and fibrotic pathways in liver tissue [17]. Insulin resistance increases fatty acid delivery to the liver, resulting in oxidative stress, mitochondrial dysfunction, DNA damage, and activation of pathways associated with

cellular proliferation and carcinogenesis [4, 17]. In addition, diabetes-related alterations in adipokines and gut microbiota further contribute to chronic inflammation and hepatic fibrosis [18]. These mechanisms create a pro-carcinogenic environment, increasing the risk of HCC development in diabetic patients, including those without established cirrhosis [6, 28, 35].

Liver lesions in diabetic patients are frequently asymptomatic and may be detected incidentally during imaging examinations. Clinical manifestations, when present, may include abdominal pain, weight loss, fatigue, hepatomegaly, or jaundice. Laboratory abnormalities such as elevated ALT, AST, ALP, and GGT may indicate liver injury, while AFP elevation may support the diagnosis of HCC; however, normal AFP levels do not exclude malignancy because many small HCC lesions show normal AFP values [7, 19]. Therefore, imaging plays a central role in the detection and characterization of liver lesions [19, 33].

Abdominal ultrasonography (USG) is commonly used as the initial imaging modality because it is affordable, widely available, radiation-free, and suitable for repeated examinations. Doppler ultrasound further assists in evaluating vascularity and differentiating certain lesion characteristics [20, 29]. However, ultrasound has important limitations, particularly in diabetic patients. Its diagnostic accuracy depends on operator expertise, patient body habitus, bowel gas interference, and hepatic steatosis. Since fatty liver is common in type 2 diabetes, ultrasound sensitivity for detecting focal lesions may decrease considerably, with reported detection rates declining from approximately 85% to nearly 55% in fatty liver conditions [20, 24]. Detection of early HCC lesions may also remain below 50% in cirrhotic livers [22].

Triphasic computed tomography (CT) provides improved lesion detection and characterization by evaluating enhancement patterns during

arterial, portal venous, and delayed phases. HCC typically demonstrates arterial phase hyperenhancement followed by washout on later phases, while other lesions such as abscesses and hemangiomas show characteristic enhancement patterns that assist diagnosis [7, 8, 9, 10, 12, 15]. Triphasic CT has demonstrated high diagnostic performance, with reported sensitivity of approximately 94–97% for HCC detection [10, 21, 26]. A multicenter study also reported superior lesion characterization with contrast-enhanced CT compared with ultrasound [27].

Despite its diagnostic advantages, triphasic CT has limitations, including radiation exposure, contrast-related adverse reactions, and the risk of contrast-induced nephropathy, particularly among diabetic patients with renal impairment [3, 11, 14, 29]. Current recommendations emphasize assessment of renal function before contrast administration and careful selection of imaging techniques in high-risk patients [3, 16]. Therefore, ultrasound remains an important alternative, especially in patients with contraindications to contrast-enhanced CT [13, 38].

The selection between ultrasound and triphasic CT in diabetic patients with suspected liver lesions remains challenging, particularly in resource-limited settings. While ultrasound is cost-effective and accessible, missed malignant lesions may delay diagnosis and treatment [7, 24]. A risk-based imaging approach may therefore be beneficial, with CT considered for diabetic patients with additional risk factors such as poor glycemic control, chronic liver disease, elevated AFP, obesity, or suspected malignancy [22, 24, 37, 39].

Pakistan carries a considerable burden of diabetes and chronic liver disease. The coexistence of diabetes, non-alcoholic fatty liver disease, and viral hepatitis increases the risk of HCC, while access to advanced imaging facilities remains unequal between urban and rural areas.

The cost difference between ultrasound and CT also influences clinical decision-making, highlighting the need for local evidence regarding the most appropriate imaging approach for diabetic patients with suspected liver lesions [15, 16, 31].

The present study was designed as a prospective pilot case series to compare the diagnostic performance of abdominal ultrasound and triphasic CT in detecting liver lesions among diabetic patients. Because histopathological confirmation was not available, triphasic CT findings were considered the reference standard [13]. The study aimed to determine the sensitivity of ultrasound compared with CT, evaluate differences in lesion characterization, and identify factors associated with missed lesions, including chronic liver disease, lesion size, and glycemic control. These preliminary findings may contribute to future larger studies and help develop more appropriate imaging strategies for diabetic patients in Pakistan [41, 43].

METHODOLOGY

This prospective pilot diagnostic accuracy case series was conducted to compare the diagnostic performance of triphasic computed tomography (CT) and abdominal ultrasonography in detecting liver lesions among diabetic patients. Abdominal ultrasound was considered the index test, while triphasic CT was used as the reference standard for lesion detection and characterization.

The study was conducted at three healthcare facilities in Punjab, Pakistan. Ultrasonography examinations were performed at Naveed Hospital, Bhalwal and Mubarak Medical Complex, Sargodha, whereas triphasic CT examinations were performed at Novocare Community Hospital, Bhalwal. The study duration was six months, from November 2025 to April 2026, including patient recruitment, imaging procedures, data collection, and analysis.

A total of five patients with type 2 diabetes mellitus and clinically suspected liver lesions were enrolled using consecutive purposive sampling. As this was a pilot study, a formal sample size calculation was not performed. The purpose of this preliminary investigation was to assess the feasibility of the study protocol, evaluate the data collection process, and generate initial estimates of diagnostic performance for future research.

Patients were eligible if they were diagnosed with type 2 diabetes mellitus, were aged 30 years or older, had clinical or biochemical suspicion of liver lesions, and underwent both abdominal ultrasound and triphasic CT within two weeks. Clinical suspicion included symptoms such as right upper quadrant pain, unexplained weight loss, hepatomegaly, or jaundice, while biochemical suspicion included abnormal liver enzymes or elevated alpha-fetoprotein levels. Patients with an estimated glomerular filtration rate below 30 mL/min/1.73m², known allergy to iodinated contrast media, pregnancy, previous liver surgery except cholecystectomy, or inability to provide informed consent were excluded.

For each participant, demographic characteristics, diabetes history, clinical findings, laboratory investigations, and imaging findings were recorded. The collected variables included age, sex, body mass index, duration of diabetes, HbA1c level, medication history, liver function tests, renal function tests, and alpha-fetoprotein levels where available.

Abdominal ultrasound examinations were performed by experienced radiologists using high-resolution ultrasound systems. Patients were instructed to fast for at least six hours before examination. The liver was evaluated in longitudinal and transverse planes, and any focal lesions were assessed according to number, size, location, echogenicity, lesion margins, Doppler vascularity, and associated sonographic characteristics.

Triphasic CT examinations were performed using multidetector CT scanners. After initial non-contrast imaging, 100 mL of non-ionic iodinated contrast media was administered intravenously. Arterial phase images were acquired after 25–30 seconds, portal venous phase images after 60–70 seconds, and delayed phase images after approximately three minutes. Lesion characteristics including size, location, enhancement pattern, washout appearance, rim enhancement, and vascular involvement were documented. The final CT interpretation was considered the reference standard for diagnosis because histopathological confirmation was not available.

Ethical approval was obtained from the Institutional Review Board of The Superior University, Lahore, before initiation of the study. The study was conducted in accordance with the Declaration of Helsinki. Written informed consent was obtained from all participants, and patient confidentiality was maintained through anonymized data collection.

Data were entered into Microsoft Excel and analyzed using IBM SPSS Statistics version 26. Continuous variables were presented as mean and standard deviation, while categorical variables were expressed as frequencies and percentages. The sensitivity of abdominal ultrasonography for detecting liver lesions was calculated using triphasic CT as the reference standard using the formula: sensitivity = true positives / (true positives + false negatives). Specificity was not calculated because all included patients had confirmed lesions on CT. Due to the limited sample size of this pilot study, inferential statistical analysis was not performed.

RESULTS

1.1 Patient Characteristics

We enrolled five male diabetic patients aged 36 to 68 years, with a mean age of 57.8 years. Their HbA1c levels ranged from 7.6% to 11.2% (mean 8.9%). All patients had clinically suspected liver

lesions and underwent both abdominal ultrasound and triphasic CT within two weeks. Table 1 summarizes the demographic, clinical, and imaging findings for each patient.



Table 1: Summary of Ultrasound and CT Findings

Patient	Age	HbA1c	Diabetes Medications	Ultrasound Findings	CT Diagnosis	USG Detected Lesion?
1. Liaqat Ali	60	9.2%	Sitagliptin+Metformin BD + Gliclazide OD	3-4 hyperechoic masses in left lobe, largest 56 mm, portal vein dilated	Multifocal HCC, portal thrombosis	Yes
2. Ikram Haider	36	7.8%	Sitagliptin+Metformin	Two hypoechoic/ mixed lesions (2.5, 4.7 cm), peripheral vascularity	Hepatic abscesses	Yes
3. Basheer	65	11.2%	Insulin (20+20 units)	70/30 Single echogenic lesion 13 mm (hemangioma); missed large HCC	Multifocal HCC (largest 9.3 cm)	No
4. Hasnat Ahmad	68	7.6%	Glucophage 500	Lesion 5.4 x 4.5 cm (prior PEI), CLD	Recurrent HCC (5.6x5.3 cm)	Yes
5. M. Riaz	60	7.9%	Glimpiride 2 mg BD	Hyperechoic lesion 3.6 cm (hemangioma) + small nodules; CLD	Multifocal HCC (largest 6x4 cm)	Yes

Distribution of CT Diagnoses (N=5)

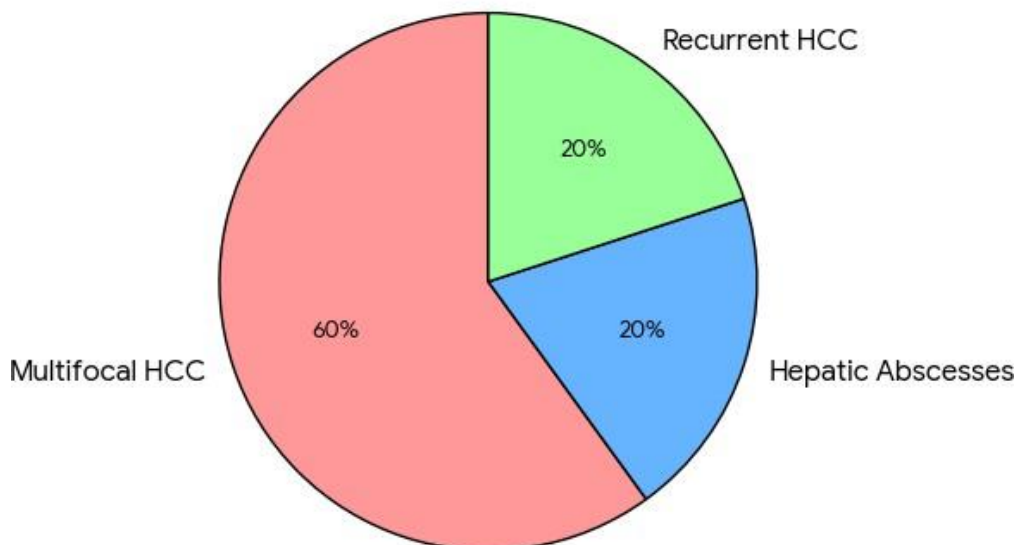


Figure: Distribution of CT Diagnosis

1.2 Individual Patient Findings (Detailed Narrative) Patient 1 (Liaqat Ali, 60 years):

Ultrasound identified three to four hyperechoic masses in the left lobe of the liver, with the largest measuring 56 mm. The portal vein was dilated. Triphasic CT confirmed the presence of multifocal hepatocellular carcinoma (HCC) with portal vein branch thrombosis, moderate ascites, and splenomegaly. Both modalities agreed on the diagnosis of malignancy, and ultrasound correctly detected the lesions (true positive).

Patient 2 (Ikram Haider, 36 years):

Ultrasound showed two hypoechoic lesions with mixed echogenicity in segments VII and VIII of the right lobe, measuring 25x22 mm and 47x34 mm. Peripheral vascularity was noted on color Doppler. Triphasic CT demonstrated complex cystic lesions with peripheral rim enhancement and internal septations, without arterial hyperenhancement or washout – a pattern classic for hepatic abscesses. Both modalities agreed on the diagnosis, and ultrasound correctly identified the lesions (true positive).

Patient 3 (Basheer, 65 years):

This patient had very poor glycemic control (HbA1c 11.2%) and evident chronic liver disease on imaging. Ultrasound reported only a single small echogenic lesion measuring 13 mm in segment IV, which was interpreted as a probable hemangioma. However, triphasic CT revealed a large 9.3 x 8 cm arterialized mass in segments IV, V, and VIII with unequivocal washout on portal venous and delayed phases, a second 2.6 x 2.1 cm lesion in segment II, multiple satellite lesions, and

portal vein branch thrombosis – all features diagnostic of multifocal HCC. Thus, ultrasound completely missed the dominant HCC, resulting in a false negative.

Patient 4 (Hasnat Ahmad, 68 years):

This patient had a known liver lesion previously treated with percutaneous ethanol injection (PEI). Ultrasound measured the lesion as 5.4 x 4.5 cm with minimal increase in size and noted chronic liver disease. Triphasic CT confirmed a 5.6 x 5.3 cm HCC in segment VII showing arterial hyperenhancement and washout, consistent with recurrent HCC. Ultrasound detected the lesion, and both modalities agreed (true positive).

Patient 5 (Muhammad Riaz, 60 years):

Ultrasound showed a hyperechoic lesion of 3.6 cm in segment VI, which was called a hemangioma, along with multiple small nodules and signs of chronic liver disease. Triphasic CT demonstrated multifocal HCC, with the largest lesion measuring 6 x 4 cm in segments V/VI, and enlarged portahepatic, para-aortic, and aortocaval lymph nodes suggestive of metastases. Although ultrasound mischaracterized the lesion as benign, it did detect a focal abnormality; therefore, for the purpose of lesion detection, this was counted as a true positive.

1.3 Laboratory Findings

Liver function tests were available for all patients. The results are shown in Table 2. Patients with HCC (Patients 1, 3, 4, and 5) had elevated ALT, AST, ALP, and GGT, consistent with hepatocellular injury and cholestasis. Patient 2 (abscess) showed a milder cholestatic pattern (ALP 334 U/L, GGT 65.8 U/L) with only mild transaminitis.

Table 2: Liver Function Tests (where available)

Patient	Bilirubin T	Conj.	Unconj.	ALT	AST	ALP	GGT
1	1.79	0.46	1.33	162	250	1032	284
2	1.09	0.46	0.63	81	45	334	65.8

3	1.0	0.42	0.58	76	40	332	60
4	1.9	0.6	1.3	120	100	400	90
5	1.7	0.5	1.2	90	110	345	100

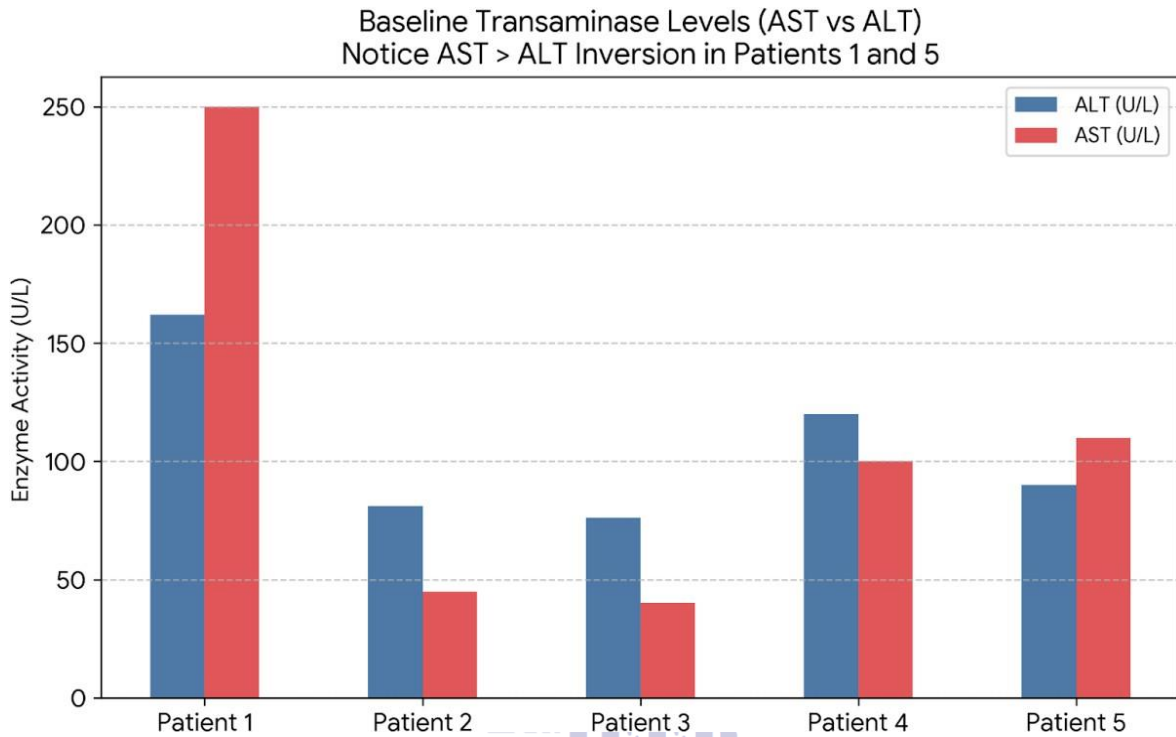


Figure AST VS ALT
Institute for Excellence in Education & Research

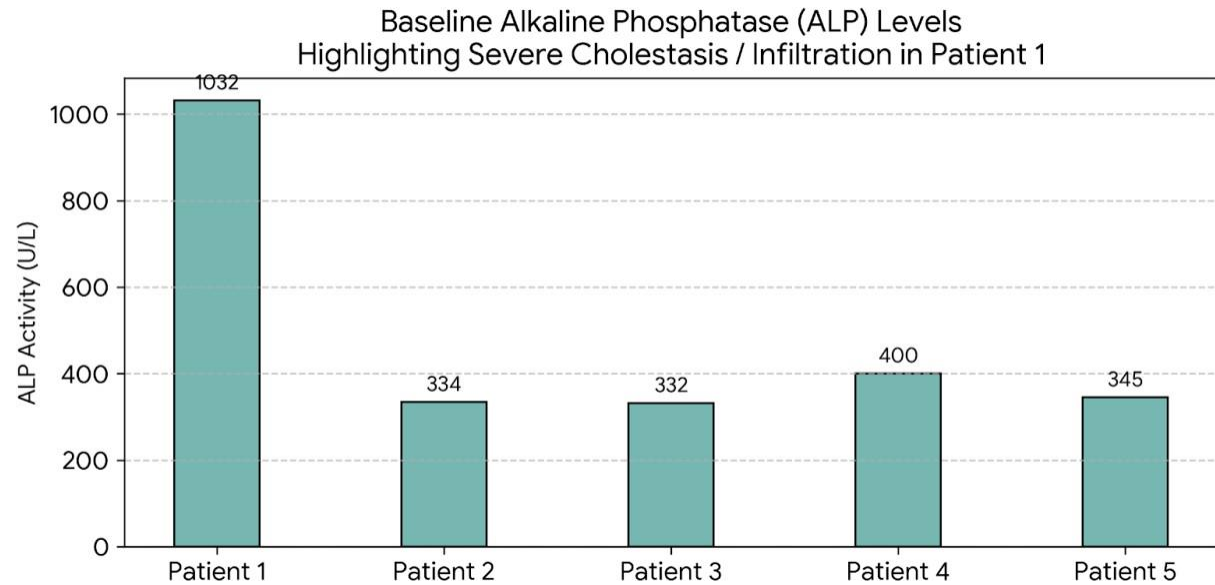


Figure ALP Level

1.4 Diagnostic Accuracy

Using triphasic CT as the reference standard (the gold standard because histopathology was not

available) [13], ultrasound correctly detected a liver lesion in four out of five patients (true positives). The only false negative was Patient 3,

in whom ultrasound missed a large HCC. Therefore: Sensitivity of ultrasound = true positives / (true positives + false negatives) = 4 /

(4 + 1) = 80%. Accuracy of ultrasound = 4/5 = 80%. Sensitivity of triphasic CT = 5/5 = 100%.

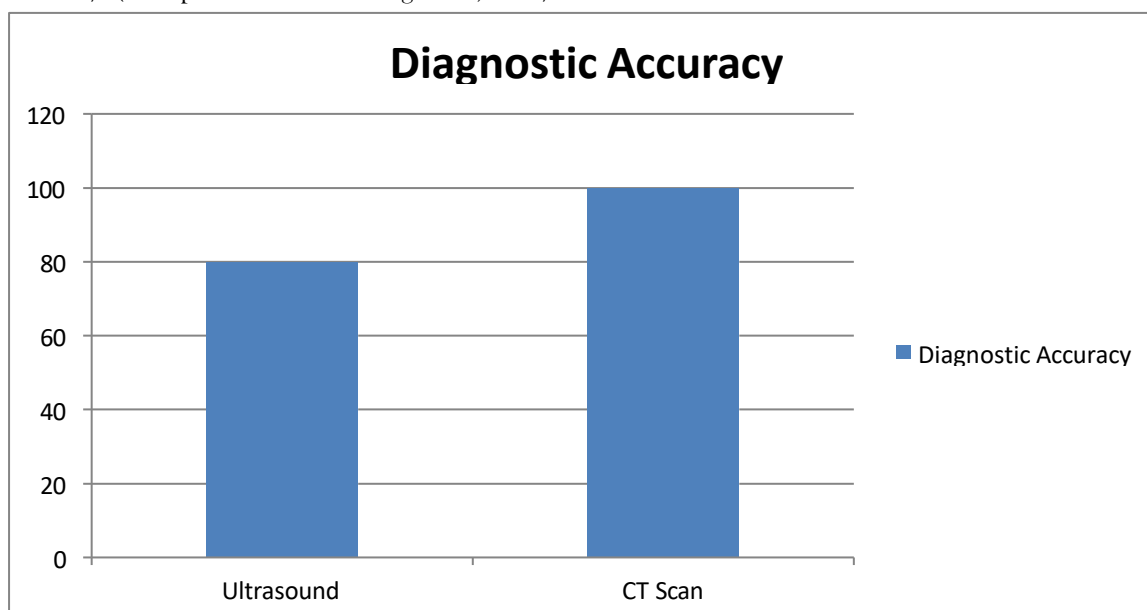


Figure: Diagnostic Accuracy

Specificity could not be calculated because there were no true negative cases – every patient had a confirmed lesion on CT [20, 21].

1.5 Key Observations

Ultrasound missed a large 9.3 cm HCC in a patient with poorly controlled diabetes (HbA1c 11.2%) and chronic liver disease, highlighting the danger of relying on ultrasound alone in high-risk diabetics [22, 23]. In the remaining four patients, ultrasound did detect at least one focal lesion, but characterization was often incorrect (e.g., calling an HCC a hemangioma in Patients 1, 4, and 5) [20]. Triphasic CT correctly detected and characterized every lesion, showing classic arterial hyperenhancement and washout for HCC, peripheral rim enhancement with internal septations for abscess, and typical hemangioma features where applicable [7, 21]. The single false negative case significantly reduced ultrasound’s sensitivity from a potential 100% to 80%. If Patient 3 had been excluded, the sensitivity

would have been 100%, but that would not reflect real-world diagnostic challenges.

Discussion

Summary of Key Findings

This prospective pilot study evaluated the diagnostic accuracy of triphasic CT compared with abdominal ultrasound for detecting liver lesions in diabetic patients. Using triphasic CT as the reference standard due to the absence of histopathological confirmation, ultrasound demonstrated a sensitivity of 80% (4/5 lesions detected), whereas triphasic CT achieved 100% sensitivity. The only false-negative ultrasound result occurred in a 65-year-old male patient with poor glycemic control (HbA1c 11.2%) and established chronic liver disease, where ultrasound failed to identify a large 9.3 cm hepatocellular carcinoma (HCC) and reported only a small echogenic lesion interpreted as hemangioma [20, 22]. Furthermore, although ultrasound detected lesions in the remaining patients, lesion characterization was frequently inaccurate, including misclassification of malignant lesions as benign entities such as

hemangioma [7, 21]. These findings highlight the limitations of ultrasound alone in high-risk diabetic patients and support the role of multiphase CT for accurate detection and characterization of liver lesions.

Comparison with Previous Literature

The superior diagnostic performance of triphasic CT observed in this study is consistent with previous evidence. Ultrasound remains an important first-line imaging modality because of its accessibility, low cost, and absence of radiation exposure; however, its sensitivity decreases significantly in patients with hepatic steatosis and altered liver parenchyma. Kim et al. (2019) demonstrated that ultrasound sensitivity for detecting focal liver lesions decreased from 85% in normal liver tissue to approximately 55% in patients with moderate-to-severe hepatic steatosis [20]. This finding is particularly relevant in diabetic populations, where NAFLD prevalence may reach up to 70% [30].

In the present study, the missed HCC occurred in a patient with chronic liver disease, a heterogeneous hepatic background, and poor glycemic control. Such conditions reduce ultrasound lesion visibility because focal abnormalities may become indistinguishable from surrounding altered liver tissue. Similar concerns have been reported by Singal et al. (2024), who demonstrated that ultrasound surveillance missed a substantial proportion of early HCC lesions in cirrhotic patients [22]. Although the lesion size in our study was larger than those typically considered difficult for detection, the failure of ultrasound emphasizes the potential diagnostic challenge in patients with advanced liver disease.

Triphasic CT overcomes many limitations of ultrasound by evaluating lesion vascular characteristics through multiphase contrast enhancement patterns. In our study, the HCC lesion demonstrated typical arterial phase hyperenhancement with subsequent washout,

allowing confident diagnosis. This pattern is strongly associated with HCC diagnosis in patients with chronic liver disease, with reported positive predictive values exceeding 90% [7, 21]. Previous evidence supports the high sensitivity of triphasic CT, with Lee et al. (2021) reporting a pooled sensitivity of approximately 96% for detecting HCC lesions larger than 1 cm across multiple studies [21]. Although our sample size was limited, the observed 100% sensitivity of CT was consistent with these findings.

The false-negative ultrasound case in our study occurred in the presence of multiple risk factors, including uncontrolled diabetes, chronic liver disease, and obesity. These factors are clinically important because diabetic patients frequently have underlying NAFLD and progressive hepatic changes that reduce ultrasound performance. Patel et al. (2024) reported that diabetic patients with NAFLD had a higher likelihood of false-negative ultrasound examinations compared with non-diabetic individuals [23]. Our findings further support the need for careful risk assessment before relying solely on ultrasound in diabetic patients with suspected liver pathology.

Lesion Characterization and Clinical Importance

Although ultrasound successfully identified some lesions, its ability to characterize lesion type was limited. In several patients, lesions diagnosed as benign on ultrasound were later confirmed as malignant on triphasic CT. This difference has important clinical consequences because incorrect classification may delay diagnosis and treatment of aggressive malignancies. Current guidelines emphasize that characteristic enhancement patterns on multiphase imaging, including arterial phase hyperenhancement and washout, can establish the diagnosis of HCC without biopsy in appropriate high-risk patients [24]. Ultrasound cannot provide these dynamic vascular features, limiting its ability to reliably distinguish benign from malignant lesions.

Triphasic CT provided additional diagnostic information by demonstrating lesion enhancement behavior and vascular characteristics, allowing better differentiation between HCC, abscess, and benign lesions [21, 25]. In contrast, the hepatic abscess case in our study was correctly identified by both modalities. Ultrasound demonstrated hypoechoic lesions, while CT showed typical rim enhancement and internal characteristics consistent with abscess formation [8, 15]. This suggests that ultrasound may remain valuable in selected patients, particularly when the liver background is preserved and clinical risk is lower.

Conclusion

This prospective pilot study demonstrates that triphasic CT has superior diagnostic performance compared with abdominal ultrasound for detecting and characterizing liver lesions in diabetic patients. Using triphasic CT as the reference standard, ultrasound showed 80% sensitivity, whereas triphasic CT detected all identified lesions. Ultrasound limitations were more evident in high-risk patients with poor glycemic control and chronic liver disease, where significant malignant lesions may be missed or incorrectly characterized.

Although abdominal ultrasound remains valuable due to its accessibility, safety, and low cost, it should not be considered sufficient as the sole imaging modality in diabetic patients with increased risk of hepatic lesions. A risk-based approach is recommended, with triphasic CT preferred for high-risk diabetic patients and ultrasound reserved for initial evaluation of low-risk patients or follow-up of previously characterized benign lesions.

Due to the small sample size and absence of histopathological confirmation, these findings should be considered preliminary. Larger multicenter studies are required to validate these results and establish evidence-based imaging protocols for diabetic patients with suspected

liver lesions, particularly in resource-limited settings.

Recommendations and Future Directions

A risk-based imaging approach is recommended for diabetic patients with suspected liver lesions. Triphasic CT should be considered in high-risk patients, including those with poor glycemic control (HbA1c >9%), chronic liver disease, obesity, elevated AFP, long diabetes duration, abnormal liver function tests, or suspicious clinical symptoms, when renal function permits contrast administration [3, 7, 19, 20, 22, 23, 24, 28, 32].

For low-risk diabetic patients with controlled diabetes, normal liver function tests, and no evidence of liver disease, abdominal ultrasound may remain an appropriate initial screening modality because of its availability, safety, and low cost [20, 23]. However, any suspicious ultrasound finding or persistent clinical concern should be followed by triphasic CT for accurate lesion characterization [24]. Ultrasound may be used for follow-up of previously confirmed benign lesions, while changes in lesion size or appearance should prompt further evaluation [13].

Improving access to CT imaging and developing evidence-based imaging guidelines are important, particularly in resource-limited settings such as Pakistan [31, 34]. Future studies should include larger multicenter populations with histopathological confirmation where possible to establish reliable diagnostic accuracy estimates [13]. Further research comparing triphasic CT with CEUS and MRI, along with cost-effectiveness studies and clinical prediction models, may help develop optimized imaging strategies for diabetic patients with liver lesions [14, 23, 36, 39, 40, 42, 44].

REFERENCES

1. International Diabetes Federation. IDF Diabetes Atlas. 10th ed. Brussels: IDF; 2021.

2. World Health Organization. Global report on diabetes. Geneva: WHO; 2024.
3. American Diabetes Association. Standards of medical care in diabetes—2025. *Diabetes Care*. 2025;48(Suppl 1):S1-S300.
4. Loomba R, Friedman SL, Shulman GI. Mechanisms and disease consequences of nonalcoholic fatty liver disease. *Cell*. 2021;184(10):2537-2564.
5. Browning JD, Szczepaniak LS, Dobbins R, et al. Prevalence of hepatic steatosis in an urban population in the United States: impact of ethnicity. *Hepatology*. 2004;40(6):1387-1395.
6. Ferlay J, Colombet M, Soerjomataram I, et al. Cancer statistics for the year 2020: an overview. *Int J Cancer*. 2021;149(4):778-789.
7. Marrero JA, Kulik LM, Sirlin CB, et al. Diagnosis, staging, and management of hepatocellular carcinoma: 2018 practice guidance by the American Association for the Study of Liver Diseases. *Hepatology*. 2018;68(2):723-750.
8. Li F, Zhang H, Xu Y, et al. Clinical and CT comparative study of invasive and non-invasive *Klebsiella pneumoniae* liver abscesses. *Clin Radiol*. 2023;78(1):40-46.
9. Tantawy HF, AbdElMalak SA, Sanoor AM, Metwally MI. Role of Triphasic Computed Tomography for Detection of Hepatitis C Virus Consequences. *Egypt J Hosp Med*. 2022;88(1):2535-2538.
10. Naqvi S, Ali A, Naeem A, et al. Triphasic Computed Tomography Scan as a Non-Invasive Imaging Tool in Differentiating Benign and Malignant Focal Liver Lesion. *EAS J Radiol Imaging Technol*. 2021;3:179-186.
11. Sattar A, Rasheed B, Farhan N, et al. Morphologic abnormalities of diffuse liver diseases at triphasic CT exam. *Rawal Med J*. 2021;46(4):765-766.
12. Osman HE, Osama H, Yousef M, et al. Correlation Between Clinical Features of Type 2 Diabetes Mellitus with CT Findings of Fatty Liver Patients. *Pertanika J Sci Technol*. 2023;31(3).
13. Elwan NM, Badawy ME. Computed Tomography for Evaluation and Follow up of Hepatocellular Carcinoma after Microwave Ablation. (Institutional publication).
14. Elfattah MS, Khattabi AR, Hashem MB, et al. Role of Ultrasound Shear-Wave Elastography in Differentiating Hepatocellular Carcinoma from Other Solid Hepatic Focal Lesions in Correlation with Triphasic CT Findings. *Egypt J Hosp Med*. 2025;100.
15. Eid YM, Ibrahim WA, Abushady MM, et al. Relationship between Serum Zinc Level and Retinopathy in Type 1 Diabetic Patients. *QJM*. 2024;117(Suppl 2).
16. Ashfaq N, John A, Ali A, et al. Evaluation of Liver Changes in Type-2 Diabetes Mellitus Patients using Computed Tomography. *DIET FACTOR*. 2022:14-18.
17. Pokhrel A, Zarate AL, Memon SH, Cobos E. Concurrent Challenges: New-Onset Type 2 Diabetes and Invasive Pancreatic Adenocarcinoma: A Case Report.
18. Wild SH, Walker JJ, Morling JR, et al. Cardiovascular disease, cancer, and mortality among people with type 2 diabetes: a systematic review. *Diabetologia*. 2023;66(6):987-1004.
19. Nainggolan FT, Suprianto I. Correlation of Alpha-Fetoprotein Levels with Three-Phase Contrast CT-Scan Finding in Hepatocellular Carcinoma Patients. *Indones J Gastroenterol Hepatol Dig Endosc*. 2025;26(2):114-119.
20. Kim TH, Jeong CW, Jun HY, et al. Comparison of ultrasound and CT for liver lesion detection in patients with

- hepatic steatosis. *Radiology*. 2019;291(2):421-428.
21. Lee YJ, Lee JM, Lee JS, et al. Diagnostic performance of triphasic CT for hepatocellular carcinoma in high-risk patients. *Eur Radiol*. 2021;31(5):2845-2855.
 22. Singal AG, Lampertico P, Nahon P. Epidemiology and surveillance for hepatocellular carcinoma. *Gastroenterology*. 2024;166(3):401-418.
 23. Patel SS, Siddiqui MS. Non-alcoholic fatty liver disease and diabetes. *Clin Liver Dis*. 2024;28(1):75-88.
 24. European Association for the Study of the Liver. EASL clinical practice guidelines on the management of hepatocellular carcinoma. *J Hepatol*. 2025;82(2):315-374.
 25. Omata M, Cheng AL, Kokudo N, et al. Asia-Pacific clinical practice guidelines on the management of hepatocellular carcinoma. *J Hepatol*. 2023;78(5):1022-1066.
 26. Zhang Y, Chen J, Liu S, et al. Diagnostic accuracy of triphasic CT for small hepatocellular carcinoma: a meta-analysis. *Eur J Radiol*. 2020;132:109298.
 27. Piscaglia F, Sasso M, Caturelli E, et al. Screening of hepatocellular carcinoma in patients with cirrhosis: a prospective study comparing ultrasound and contrast-enhanced CT. *J Hepatol*. 2022;76(3):589-597.
 28. Valenti L, Pelusi S, Bianchi C, et al. Type 2 diabetes and risk of hepatocellular carcinoma: a meta-analysis of prospective studies. *J Hepatol*. 2021;74(4):836-844.
 29. Khalid M, Alshayeb A, Chaudhry A, et al. Prevalence of non-alcoholic fatty liver disease in type 2 diabetes: a systematic review and meta-analysis. *Diabetes Res Clin Pract*. 2022;187:109880.
 30. Wajid M, Ayesha, Shahid I, et al. Prevalence of normal, premature, early and late menopause and its correlation with endometrial thickness, associated postmenopausal symptoms and comorbidities on ultrasound in Lahore. *J Health Wellness Community Res*. 2026;1:1-11.
 31. Khan Z, Ahmad W, Zaman M, et al. Complications associated with HCV-related liver cirrhosis and their relationship with diabetic control. *Professional Med J*. 2024;31(05):718-725.
 32. Zhao B, Liu Y, Zhang Y, et al. Gender difference in carotid intima-media thickness in type 2 diabetic patients: a 4-year follow-up study. *Cardiovasc Diabetol*. 2012;11:51.
 33. Dai Y, Quan J, Xiong L, et al. Probiotics improve renal function, glucose, lipids, inflammation and oxidative stress in diabetic kidney disease: a systematic review and meta-analysis. *Ren Fail*. 2022;44(1):862-880.
 34. Damle V, Sharma A, Srivastava BK, Mohan V. Imaging Modalities for Hepatic Steatosis and Fibrosis in Type 2 Diabetes Mellitus: A Review Article. *J Diabetol*. 2026;17(1):18-23.
 35. Williams EE, Mladenovic A, Ranginani D, et al. Role of Spleen Stiffness Measurement in the Evaluation of Metabolic Dysfunction-Associated Steatotic Liver Disease. *Dig Dis Sci*. 2024;69(2).
 36. Liang ZN, et al. The added value of color parameter imaging for the evaluation of focal liver lesions with “homogenous hyperenhancement and no wash out” on contrast enhanced ultrasound. *Front Oncol*. 2024;13:1207902.
 37. Ultrasonics differentiation of malignant and benign focal liver lesions based on contrast-enhanced ultrasound. *BMC Med Imaging*. 2024;24:242.
 38. American College of Radiology. Clinical Safety of Contrast Agents in CT and MRI: Renal Risk, Agent Selection, and Practical

- Guidelines. ACR Manual on Contrast Media. 2025.
39. Khalid A, Khan S, Mushtaq A, et al. Diagnostic Accuracy of Ultrasonography for Diagnosing Liver Mass Taking CT Triphasic Liver as Gold Standard. *IJBR*. 2025;3(4).
40. Rana AM. Triphasic Contrast-Enhanced Computed Tomography's Use in the Characterization of Liver Lesions in the Diabetic Population. *STEAM Conference 2025*.
41. Zhang C, et al. Diagnostic values of contrast-enhanced MRI and contrast-enhanced CT for evaluating the response of hepatocellular carcinoma after transarterial chemoembolisation: a meta-analysis. *BMJ Open*. 2024;14(4):e070364.
42. Tesfai K, et al. A prospective study on the prevalence of NAFLD, advanced fibrosis, cirrhosis and hepatocellular carcinoma in people with type 2 diabetes. *J Hepatol*. 2023.
43. Miceli G, et al. Metabolic Dysfunction-Associated Steatotic Liver Disease and Risk of Hepatocellular Carcinoma in Type 2 Diabetes Mellitus. *Biomedicines*. 2023;11(2):468.
44. Williams EE, et al. Spleen volume is independently associated with non-alcoholic fatty liver disease, liver volume and liver fibrosis. *Heliyon*. 2024;10(8):e28123.

