The Research of Medical Science Review
ISSN: 3007-1208 & 3007-1216 Volume 3, Issue 6, 2025

DIAGNOSTIC ACCURACY OF MAGNETIC RESONANCE IMAGING IN PATIENTS WITH TUBERCULOUS SPONDYLITIS, USING HISTOPATHOLOGY AS THE GOLD STANDARD

Mufliha Khan[*1], Uzma Nisar[2], Maria Kanwal[3], Asma Kiani[4], Tayyaba Nisar[5], Shah Ali Arslan[6]

[*1,2,3,4,5]*CMH Rawalpindi, Pakistan*
[6]*AFRIM Rawalpindi*

[*1]muflihakhan96@gmail.com

DOI: https://doi.org/10.5281/zenodo.21670912

Keywords
Magnetic resonance imaging; spinal tuberculosis; spondylitis; tuberculous.

Article History
Received: 08 April 2025
Accepted: 20 May 2025
Published: 05 June 2025

Copyright @Author
Corresponding Author: *
Mufliha Khan

Abstract

Objective: *To determine diagnostic accuracy of magnetic resonance imaging (MRI) in patients with tuberculosis (TB) spondylitis, using histopathology as gold standard.*

Study design: *Cross-sectional diagnostic accuracy study.*

Place and Duration: *Islamabad Diagnostic Centre, F-8 Markaz, Islamabad, from October 2024 to March 2025 (6 months).*

Methodology: *Patients (n = 90) with clinical suspicion of TB spondylitis were included through consecutive non-probability sampling. All patients underwent MRI of affected spine. Histopathological examination of biopsy or surgical tissue specimens was used as reference standard for confirmation of disease. Data were analyzed using SPSS. MRI findings were compared with histopathology through 2×2 contingency table. Sensitivity, specificity, positive predictive value (PPV), negative predictive value (NPV), diagnostic accuracy and area under the receiver operating characteristic (ROC) curve were calculated.*

Results: *Among 90 patients, 57 were males and 33 were females. Mean age was 41.35±7.03 years in males and 43.15±8.11 years in females. Mean disease duration was 9.51±4.89 months. Sensitivity of MRI was 98.59%, specificity of 84.21%, PPV of 95.89%, NPV of 94.12% and overall diagnostic accuracy of 95.56%. Area under ROC curve was 0.914 (95% CI: 0.815–1.00), indicating excellent diagnostic performance.*

Conclusion: *MRI showed better diagnostic accuracy for TB spondylitis and is valuable non-invasive tool for early diagnosis. However, histopathology still remains important for final confirmation in doubtful cases.*

INTRODUCTION

Tuberculous (TB) spondylitis, also known as spinal TB or Pott's disease, remains one of most serious forms of extrapulmonary TB because of its ability to destroy vertebral structures, produce spinal deformity and cause irreversible neurological compromise when diagnosis is delayed. Although global burden of TB has been widely recognized, spinal involvement continues to present distinct diagnostic challenge due to its relatively indolent course and nonspecific nature of early clinical symptoms such as back pain, malaise, weight loss and reduced mobility.[1, 2] In many patients, disease progresses silently until vertebral collapse, paraspinal abscess formation, epidural extension or cord compression becomes evident.[2, 3]

Early and accurate diagnosis is essential for timely initiation of anti-TB therapy and

prevention of severe disability. However, diagnosis cannot rely on clinical features alone, because spinal TB may mimic pyogenic spondylodiscitis, metastatic disease, degenerative spinal pathology and other inflammatory conditions.[4, 5] Conventional radiography technique often diagnose later after considerable bony destruction has already occurred. While laboratory markers are supportive but not specific.[2, 3] Tissue-based methods including biopsy for histopathology and microbiological testing still remain crucial for confirmation especially in uncertain cases.[5]
Magnetic resonance imaging (MRI) has become preferred modality for suspected spinal TB because it provides excellent visualization of marrow involvement, intervertebral disc changes, paravertebral, epidural soft tissue extension, abscess formation and neural compression. MRI is valuably helpful in early diagnosis when plain radiographs appear normal and it helps in defining anatomical extent of disease for treatment planning.[6, 7] Recent studies have shown particular MRI features including thin and smooth abscess walls, multilevel vertebral involvement, relative disc preservation in early stages, subligamentous spread, vertebral collapse and larger paraspinal collections may favour TB over pyogenic infection.[8, 9]
Despite these strengths, MRI is not infallible. Considerable overlap exists between TB and pyogenic spondylitis and interpretation may vary with disease stage and observer experience. Recent comparative models and meta-analysis have improved understanding of MRI-based differentiation but they emphasized imaging alone should not be regarded as absolutely definitive.[8, 9] For that reason, histopathology considered as reference standard in many studies evaluating diagnostic performance.[10]
Given clinical consequences of missed or delayed diagnosis, assessing diagnostic accuracy of MRI against histopathology remains highly relevant. Establishing sensitivity, specificity and overall validity of MRI in patients with TB spondylitis can help determine how reliably this non-invasive modality identifies disease in routine practice and whether it can support earlier diagnosis while awaiting tissue confirmation.[8, 10]

To determine the diagnostic accuracy of MRI in diagnosing TB spondylitis in suspected patients by keeping histopathology as gold standard.

Methodology

This cross-sectional diagnostic accuracy study included patients with clinical suspicion of TB spondylitis presenting to Islamabad Diagnostic Centre, F-8 Markaz, Islamabad, from October 2024 to March 2025 (6 months). Sample size calculated for this study was 90, by estimating MRI sensitivity and specificity of 91.2% and 83.1%, prevalence of Tb spondylitis was 35%[11], confidence interval of 95% and margin of error of 10%, respectively.
Data was collected by consecutive non-probability sampling.

Inclusion Criteria: Patients with persistent back pain from at least 6 months, constitutional symptoms suggestive of TB such as loss of appetite and weight loss of 10-15% from last months and supportive laboratory or clinical findings raising suspicion of spinal TB including increase in ESR level 15mm per hour and positive results of AFB spectrum, were included.

Exclusion Criteria: Patients contraindicated to MRI, including cardiac pacemakers, metallic ocular implants, defibrillators or severe claustrophobia, with known hypersensitivity to contrast medium, those unwilling to participate and those with incomplete clinical or histopathological data, were excluded.
All enrolled patients underwent MRI of involved spine using a 1.5 Tesla scanner. MRI findings suggestive of TB spondylitis including vertebral body destruction, altered marrow signal intensity, disc involvement, paravertebral or epidural collections and end-plate irregularity, recorded by radiologist. For confirmation, tissue samples from affected vertebral or paravertebral region were obtained by biopsy or during surgical debridement and sent for histopathological examination. Histopathology will be taken as gold standard for final diagnosis. MRI findings will then be compared with histopathological results to determine diagnostic accuracy.

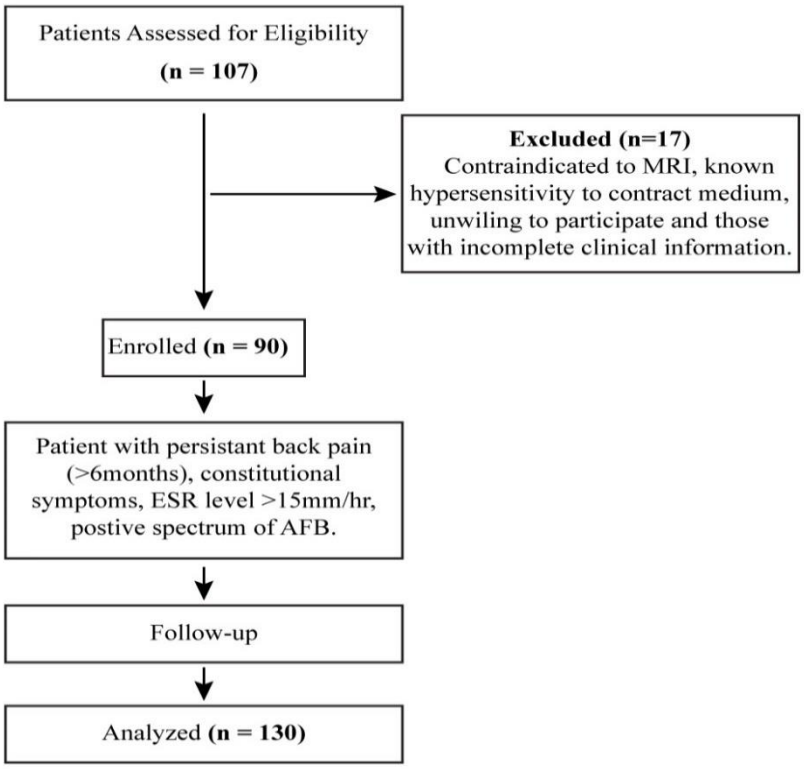

Figure 1. Pateint Selection Flow Chart.

Data was entered and analyzed by using IBM Statistical Package for Social Sciences, version 25.0. Descriptive statistics was applied to summarize study variables. Age, BMI and disease duration will be presented as mean ± standard deviation (Mean±SD), while gender, MRI findings and histopathology results will be presented as frequency and percentage. 2×2 contingency table will be constructed to compare MRI findings with histopathology, taking histopathology as gold standard. Based on this table, diagnostic accuracy of MRI will be determined by calculating sensitivity, specificity, Positive Predictive Value (PPV), Negative Predictive Value (NPV) and overall accuracy.

Results

Total of 90 patients were included in study. 57 were males and 33 were females. Mean age among male patients was 41.35±7.03 years while mean age among female patients was 43.15±8.11 years. Mean disease duration was 9.51±4.89 months, respectively.

When MRI findings were compared with histopathology, 70 patients were correctly identified by MRI as having TB spondylitis while 16 patients were correctly identified as disease-free. There were 3 false positive cases and 1 false negative case. Overall, MRI showed a sensitivity and specificity of 98.59% and 84.21%, positive predictive value (PPV) of 95.89%, negative predictive value (NPV) of 94.12% and diagnostic accuracy of 95.56%, respectively.

Receiver operating characteristic analysis further supported strong diagnostic performance of MRI. Area under curve (AUC) was 91.4% indicating excellent ability of MRI to distinguish patients with TB spondylitis from those without disease. Overall, these findings show that MRI performed very well against histopathology as gold standard.

Table I. Patients Parameters (n = 90)

Parameters	Values (Mean±SD)
Age (Year)	
Male (n = 57)	41.35±7.03

Female (n = 33)	43.15±8.11
Disease Duration (in months)	9.51±4.89

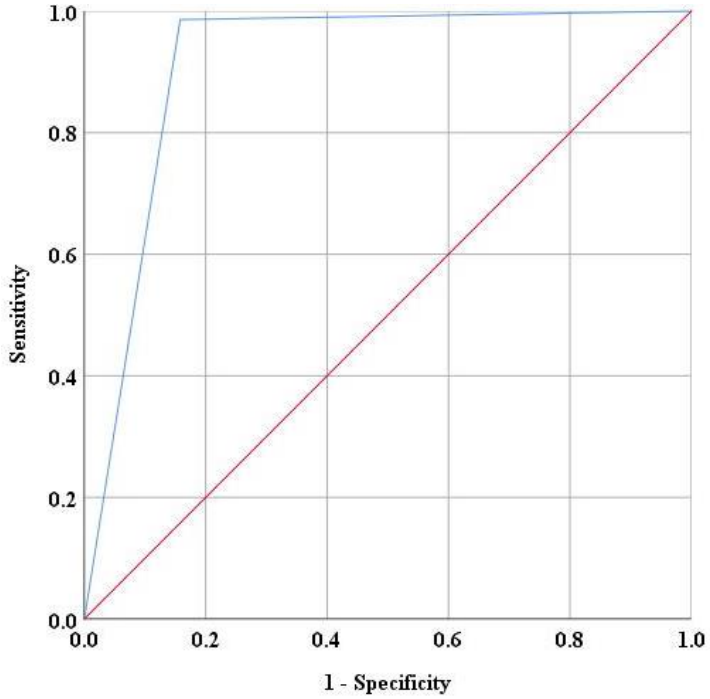

Figure 2. ROC curve of MRI (blue line) to diagnose presence of TB spondylitis.

Table II. Performance of MRI, to Diagnosis Presence of TB Spondylitis, taking Histopathology as Gold Standard (n = 90)

MRI	Histopathology	
	TB Spondylitis Present (n)	TB Spondylitis Absent (n)
TB Spondylitis Present (n)	70	3
TB Spondylitis Absent (n)	1	16
Sensitivity	98.59% (95% CI, 92.44 - 99.75[1])	
Specificity	84.21% (95% CI, 62.43 - 94.48[1])	
PPV	95.89% (95% CI, 88.6 - 98.59[1])	
NPV	94.12% (95% CI, 73.02 - 98.95[1])	
DA	95.56% (95% CI, 89.12 - 98.26[1])	

Discussion

Current study showed that MRI had very high sensitivity, strong predictive values and better overall diagnostic accuracy for TB spondylitis while keeping histopathology as gold standard. This pattern supports practical role of MRI as early and highly informative imaging tool in suspected spinal tuberculosis.[1] A study reported high MRI performance with sensitivity of 91.2% and specificity of 83.1%. While recent imaging reviews have continued to describe MRI as key modality for defining vertebral, discal, epidural and paraspinal extent of infection.[12, 13]

Pattern seen in our study data, namely very high sensitivity with somewhat lower specificity is also clinically reasonable. MRI is highly responsive to marrow edema, vertebral destruction, soft-tissue extension and abscess formation. Some of these appearances overlap with pyogenic spondylodiscitis and other inflammatory lesions. This overlap likely explains small number of false-positive cases in present series. A study showed that MRI can help in distinguishing TB from pyogenic spondylodiscitis.[14, 15] Later demonstrated that a structured diagnostic model combining selected variables improved discrimination with AUC

values of 0.841 in training group and 0.83 in validation group.[16]

Another study supported effectiveness of MRI while highlighting broad disease spectrum with which patients presented to hospital. Frequent disc involvement and para/prevertebral collections in Pott's spine with epidural collection occurring in >75% of patients.[17] Multilevel disease was far more common than single-level involvement, emphasizing that spinal TB often presents with extensive anatomical spread.[18] Together, these findings fit well with our results and suggest that, in Pakistani settings MRI is particularly valuable because it diagnosed well in single examination. MRI should not be viewed as replacement for tissue confirmation as its greatest strength is early suspicion, anatomical mapping and guidance for further management. But etiological confirmation remained important when imaging overlaps with pyogenic infection or other mimics. Recent evidence supported this combined approach. Zhu et al. showed integrating MRI with laboratory and clinical variables improved diagnostic classification across different infectious spondylitis.[19] This strengthened rationale for using histopathology as reference standard.

Overall, AUC (0.914) in our study indicated better discriminatory ability of MRI. In practical terms, MRI can confidently support early treatment planning by helping in identification of patients who need biopsy and show disease extension that might influence surgical or conservative management. Even so, few false-positive and false-negative cases in our series are remained that MRI is highly useful but not absolute.

This study has some limitations including that the study was conducted at single centred and included relatively small sample size, so findings may not fully represent all patient populations. Analysis was mainly focused on overall MRI positivity vs histopathology. Laboratory and microbiological parameters were not incorporated into diagnostic model so multimodal comparison was not possible. These factors should be considered when interpreting results. Larger multicentre studies are needed for stronger external validity.

Conclusion

MRI demonstrated better diagnostic performance for TB spondylitis. It has stronger ability in identifying disease and assessment of spinal involvement makes it valuable non-invasive tool in suspected cases. MRI can support early diagnosis and timely management. However, histopathological confirmation remained important in doubtful cases because imaging findings may overlap with other infective or inflammatory spinal conditions.

Conflict of Interest: There is no conflict.

Author's Contribution:

Authors were engaged in thorough conceptual approach, accountability, ensuring detailed investigation, collection and analysis of data, manuscript drafting and final version of manuscript approval.

References

Khokhar ME, Khan NH, Bilal S, Ameer S. The diagnostic accuracy of magnetic resonance imaging (MRI) for detection of spinal tuberculosis (TB). Journal of Islamabad Medical & Dental College. 2022;11(2):110-3. https://doi.org/10.35787/jimdc.v11i2.641

Leowattana W, Leowattana P, Leowattana T. Tuberculosis of the spine. World journal of orthopedics. 2023;14(5):275. https://doi.org/10.5312/wjo.v14.i5.275

Shanmuganathan R, Ramachandran K, Shetty AP, Kanna RM. Active tuberculosis of spine: Current updates. North American Spine Society Journal (NASSJ). 2023;16:100267. https://doi.org/10.1016/j.xnsj.2023.100267

Li Z, Wang J, Xiu X, Shi Z, Zhang Q, Chen D. Evaluation of different diagnostic methods for spinal tuberculosis infection. BMC Infectious Diseases. 2023;23(1):695. https://doi.org/10.1186/s12879-023-08655-5

Acharya A, Panda K, Panigrahi S, Senapati SB, Mahapatra AK, Sahu K. Spinal tuberculosis: an exhaustive diagnosis. The International Journal of Mycobacteriology. 2024;13(1):96-9. https://doi.org/10.4103/ijmy.ijmy_14_24

Abid W, Ladeb MF, Chidambaranathan N, Peh WC, Vanhoenacker FM. Imaging of musculoskeletal tuberculosis. Skeletal Radiology. 2024;53(10):2081-97. https://doi.org/10.1007/s00256-023-04556-5

Ling-Shan C, Zheng-Qiu Z, Jing L, Rui Z, Li-Fang L, Zhi-Tao W, et al. Magnetic resonance imaging features for differentiating tuberculous from pyogenic spondylitis: a meta-analysis. Skeletal Radiology. 2024;53(4):697-707. https://doi.org/10.1007/s00256-023-04459-5

Wang J, Li Z, Chi X, Chen Y, Wang H, Wang X, et al. Development of a diagnostic model for differentiating tuberculous spondylitis and pyogenic spondylitis with MRI: a multicenter retrospective observational study. Spine. 2024;49(1):34-45. https://doi.org/10.1097/BRS.0000000000004848

Tanaviriyachai T, Pornsopanakorn P, Choovongkomol K, Virathepsuporn T, Piyapromdee U, Jongkittanakul S, et al. A comparative factor analysis and new magnetic resonance imaging scoring system for differentiating pyogenic versus tuberculous spondylodiscitis. Neurospine. 2024;21(2):690. https://doi.org/10.14245/ns.2448120.060

Ying JYJ, Wong SBS, Yeap PM. Revisiting imaging features of spinal tuberculosis. Singapore Medical Journal. 2025;66(10):576-81. https://doi.org/10.4103/singaporemedj.SMJ-2022-214

Batirel A, Erdem H, Sengoz G, Pehlivanoglu F, Ramosaco E, Gülsün S, et al. The course of spinal tuberculosis (Pott disease): results of the multinational, multicentre Backbone-2 study. Clinical Microbiology and Infection. 2015;21(11):1008. e9-. e18. https://doi.org/10.1016/j.cmi.2015.07.013

Crombé A, Fadli D, Clinca R, Reverchon G, Cevolani L, Girolami M, et al. Imaging of spondylodiscitis: a comprehensive updated review—multimodality imaging findings, differential diagnosis, and specific microorganisms detection. Microorganisms. 2024;12(5):893. https://doi.org/10.3390/microorganisms12050893

Hirunpat P, Panyaping T, Wongpipathpong W, Hirunpat S. Imaging clues for the diagnosis of various pathogenic causes of infectious spondylitis. Skeletal Radiology. 2025;54(11):2411-24. https://doi.org/10.1007/s00256-025-04943-0

Naselli N, Facchini G, Lima GM, Evangelisti G, Ponti F, Miceli M, et al. MRI in differential diagnosis between tuberculous and pyogenic spondylodiscitis. European Spine Journal. 2022;31(2):431-41. https://doi.org/10.1007/s00586-021-06952-8

Frel M, Białecki J, Wieczorek J, Paluch Ł, Dąbrowska-Thing A, Walecki J. Magnetic resonance imaging in differentatial diagnosis of pyogenic spondylodiscitis and tuberculous spondylodiscitis. Polish Journal of Radiology. 2017;82:71-87. https://doi.org/10.12659/PJR.899606

Huang C, Zhuo J, Liu C, Wu S, Zhu J, Chen T, et al. Development and validation of a diagnostic model to differentiate spinal tuberculosis from pyogenic spondylitis by combining multiple machine learning algorithms. Biomolecules and Biomedicine. 2024;24(2):401. https://doi.org/10.17305/bb.2023.9663

Sharma B, Panta OB, Thapa BR, Thapa P, Khadka T. Retrospective Study of Magnetic Resonance Imaging (MRI) Findings in Pott's Spine. Nepalese Journal of Radiology. 2021;11(2):11-8. https://doi.org/10.3126/njr.v11i2.40667

Afsar M, Shahab A, Samad M, Wahid G, Rehman M, Shah R. DIVERSITY OF SPINAL TUBERCULOSIS FINDINGS ON MAGNETIC RESONANCE IMAGING: A STUDY FROM A TERTIARY CARE HOSPITAL. Journal of Postgraduate Medical Institute. 2022;36(3):170-3. https://doi.org/10.54079/jpmi.36.3.3088

Zhu W, Xu Z, Zhou S, Li P, Zhao F, Wu G, et al. A comprehensive analysis of magnetic resonance imaging and laboratory features in pyogenic, tuberculous, brucellar, and fungal spondylitis. Quantitative Imaging in Medicine and Surgery. 2025;15(10):9222-37. https://doi.org/10.21037/qims-2025-605

IEER
Institute for Excellence in Education & Research