The Research of Medical Science Review
ISSN: 3007-1208 & 3007-1216 Volume 3, Issue 6, 2025

DIAGNOSTIC ACCURACY OF INTRA-OPERATIVE FROZEN SECTIONS IN DETECTING SQUAMOUS CELL CARCINOMA (SCC), KEEPING HISTOPATHOLOGY OF PERMANENT SECTION AS THE GOLD STANDARD

Dr. Ume Farwah[1*], Prof. Dr. Suneel Kumar[2], Dr. Hafsa Maqbool Memon[3], Dr. Hina Rehman[4]

[*1]*Postgraduate Resident, Department of Oral and Maxillofacial Surgery, Liaquat University of Medical & Health Sciences (LUMHS), Jamshoro, Pakistan.*
[2]*Profeesor Department of Oral and Maxillofacial Surgery, Liaquat University of Medical & Health Sciences (LUMHS), Jamshoro, Pakistan.*
[3]*Postgraduate Resident, Department of Oral and Maxillofacial Surgery, Liaquat University of Medical & Health Sciences (LUMHS), Jamshoro, Pakistan.*
[4]*Postgraduate Resident, Department of Oral and Maxillofacial Surgery, Liaquat University of Medical & Health Sciences (LUMHS), Jamshoro, Pakistan.*

DOI: https://doi.org/10.5281/zenodo.23261637

Keywords
Frozen section; permanent section; surgical margins; histopathology; diagnostic accuracy; ROC curve.

Article History
Received: 05 Apri 2025
Accepted: 05 May 2025
Published: 15 June 2025

Copyright @Author
Corresponding Author: *
Dr. Ume Farwah

Abstract

Objective:
To evaluate the diagnostic accuracy of intraoperative frozen-section examination for the assessment of surgical margins, using permanent-section histopathology as the reference standard.

Settings & Duration: *Department of Oral and Maxillofacial Surgery, Institute of Dentistry, Liaquat University of Medical and Health Sciences (LUMHS), Jamshoro/Hyderabad, Pakistan, over a period of six months following approval of the research synopsis by the Ethical Review Committee*

Methods:
This study included 234 patients undergoing surgical treatment for tumours involving the oral and maxillofacial region. Intraoperative tissue samples from the surgical margins were examined by frozen-section technique and classified as positive or negative. The final permanent-section histopathological findings were considered the reference standard. The diagnostic performance of frozen-section examination was assessed by calculating sensitivity, specificity, positive predictive value (PPV), negative predictive value (NPV), and overall diagnostic accuracy. Receiver operating characteristic (ROC) analysis was also performed.

Results:
Among 234 patients, 117 (50.0%) had positive and 117 (50.0%) had negative margins on frozen-section examination, whereas permanent-section histopathology identified 125 (53.4%) positive and 109 (46.6%) negative margins. Frozen-section examination correctly identified 111 of 125 positive margins and 103 of 109 negative margins. The sensitivity was 88.8%, specificity 94.5%, PPV 94.9%, and NPV 88.0%, with an overall diagnostic accuracy of 91.5%. ROC analysis demonstrated an area under the curve of 0.955, indicating excellent discriminatory performance.

Conclusion:
Intraoperative frozen-section examination showed high diagnostic accuracy and strong agreement with permanent-section histopathology for assessing surgical margins.

INTRODUCTION:

Histopathological examination of permanent sections remains the gold standard for diagnosing suspected malignancies in orbital and other surgical lesions.[1] Intraoperative frozen section examination provides a rapid assessment of tissue morphology and may assist surgeons in making immediate modifications to the surgical procedure when required.[2] Its use is particularly important in oncological surgery, where intraoperative assessment of tumor margins can influence the extent of resection. Because an incorrect intraoperative diagnosis may result in inappropriate surgical management, high diagnostic accuracy is essential.[3]

Frozen section examination facilitates rapid intraoperative diagnosis and is frequently used during surgical procedures to identify malignancy, assess resection margins and detect metastatic disease in lymph nodes.[4] It can also provide useful information regarding unexpected pathological conditions. The present study therefore focuses on evaluating the accuracy of frozen section diagnosis against the reference standard of permanent-section histopathology.[5,6]

Head and neck cancers represent an important health burden in Pakistan. Oral squamous cell carcinoma is the predominant malignant tumor of the oral cavity and is generally managed by surgical excision.[7,8] Complete removal of the primary tumor is an important prognostic consideration, and the status of the surgical margin has a significant role in subsequent disease control. A final histopathological margin of 5 mm has traditionally been considered adequate in the literature.[9,10]

Despite these findings, discrepancies between frozen and permanent sections remain clinically relevant. In addition, there is limited local evidence regarding the accuracy of frozen-section examination for identifying tumor-free margins in patients with oral squamous cell carcinoma. This gap in local evidence provided the rationale for conducting the present study.

The primary objective of the present study was to determine the diagnostic accuracy of intraoperative frozen section in detecting squamous cell carcinoma of the oral cavity, using permanent-section histopathology as the reference standard.

MATERIALS AND METHODS

This cross-sectional study was conducted in the Department of Oral and Maxillofacial Surgery, Institute of Dentistry, Liaquat University of Medical and Health Sciences (LUMHS), Jamshoro/Hyderabad, Pakistan, over a period of six months following approval of the research synopsis by the Ethical Review Committee. The required sample size was 234 patients and was calculated using previously reported sensitivity and specificity of 88.81% and 94.84%, respectively.[18] A 95% confidence level and the specified precision were used for the calculation. The estimated sample size was 210 patients for sensitivity and 43 for specificity; after accounting for a 10% dropout rate, the final sample size was set at 234 patients. The calculation was performed using the Wnarifin sample size calculator based on the methodology described by Buderer for diagnostic accuracy studies.[19,20] Patients were recruited using non-probability consecutive sampling.

Patients aged 5–80 years of either sex with biopsy-proven squamous cell carcinoma (SCC) of the oral cavity who underwent surgical resection at LUMHS were included. Lesions involving the tongue, buccal mucosa, maxilla, and mandible and classified as stage I–IV according to the TNM classification were eligible. Patients undergoing surgery with curative intent were included, whereas those with metastatic disease, palliative treatment, lesions other than oral SCC, unavailable clinical history or preoperative

investigations, or a history of previous radiation therapy, chemotherapy, or surgery were excluded. Before enrollment, the study objectives, procedures, potential risks, and benefits were explained to all participants, and written informed consent was obtained. Data were collected using a predesigned structured questionnaire. All included patients subsequently underwent surgical excision with curative intent, with an attempt to maintain a 1-cm gross margin around the tumor.

For intraoperative frozen-section examination, unfixed tissue specimens were subjected to gross examination, and representative sections were selected by the pathologist. The tissue was placed on a metallic block, covered with optimal cutting temperature (OCT) compound, rapidly frozen at approximately −20°C, and sectioned using a cryostat. Sections measuring 5 µm in thickness were stained with hematoxylin and eosin (H&E), and the examination was completed within approximately 5–10 minutes of tissue excision. Following tumor removal, specimens from the surrounding mucosal and deep margins of the tumor bed were also examined by frozen section to assess microscopic tumor involvement.

The remaining tissue was fixed in formalin, embedded in paraffin, sectioned, and stained with H&E for permanent histopathological examination. Both frozen and permanent sections were reviewed and correlated by an experienced attending pathologist. Resection margins were considered positive when dysplasia, carcinoma in situ, or invasive carcinoma was identified at the margin or within 5 mm of it. When a positive margin was identified on frozen section, further resection was performed where surgically feasible until a negative margin was achieved. Frozen-section findings were subsequently compared with the corresponding permanent-section diagnosis, which served as the reference standard. A true-positive result was defined as tumor identified on both frozen and permanent sections, while a true-negative result indicated absence of tumor on both examinations. A false-positive result was defined as tumor reported on frozen section but absent on permanent section, whereas a false-negative result indicated a negative frozen section with a positive permanent-section diagnosis.

The diagnostic performance of frozen-section examination was assessed by calculating sensitivity, specificity, positive predictive value (PPV), negative predictive value (NPV), and diagnostic accuracy. Sensitivity represented the proportion of permanent-section-positive cases correctly identified by frozen section, while specificity represented the proportion of permanent-section-negative cases correctly identified as negative. PPV and NPV represented the proportions of positive and negative frozen-section results, respectively, that were confirmed by permanent histopathology. Diagnostic accuracy was calculated as the proportion of correctly classified cases among all evaluated patients.

Data were analyzed using SPSS version 26. Continuous variables were presented as mean ± standard deviation. Categorical variables, were presented as frequencies and percentages. A 2 × 2 contingency table was constructed to compare frozen-section findings with permanent-section histopathological findings. Sensitivity, specificity, PPV, NPV, and diagnostic accuracy were calculated from this comparison. ROC curve was made to determine the Area Under Curve (AUC).

Results

A total of 234 patients were included in the study. The demographic and clinical characteristics of the patients are presented in **Table 1**. The majority of patients were aged 51–60 years (106, 45.3%), followed by those aged 41–50 years (63, 26.9%). Thirty-four (14.5%) patients were aged ≤40 years, while 31 (13.2%) were aged >60 years. There were 130 (55.6%) male and 104 (44.4%) female patients. The most frequent tumour site was the buccal mucosa (133, 56.8%), followed by the tongue (59, 25.2%), mandible (23, 9.8%), and maxilla (19, 8.1%). Tumour size was ≤4 cm in 145 (62.0%) patients and >4 cm in 89 (38.0%). Regarding TNM stage, 82 (35.0%) patients had stage I disease, 115 (49.1%) had stage II, 23 (9.8%) had stage III, and 14 (6.0%) had stage IV disease. Histologically, most tumours were grade 2 (132, 56.4%), followed by grade 1 (66, 28.2%) and grade 3 (36, 15.4%).

On intraoperative frozen-section examination, margins were reported as positive in 117 (50.0%) and negative in 117 (50.0%) patients. On permanent-section histopathological examination, considered the reference standard, 125 (53.4%) patients had positive margins and 109 (46.6%) had negative margins (**Table 1**).

The comparison between frozen-section findings and permanent-section histopathology is shown in (**Table 2**). Of the 125 patients with positive margins on permanent-section examination, 111 were correctly identified as positive by frozen section (true positive), whereas 14 were incorrectly classified as negative (false negative). Among the 109 patients with negative permanent-section margins, 103 were correctly identified as negative by frozen section (true negative), while 6 were classified as positive (false positive).

The diagnostic performance of frozen-section examination is presented in (**Table 3**). Frozen-section examination demonstrated a sensitivity of 88.8% and specificity of 94.5%. The positive predictive value was 94.9%, while the negative predictive value was 88.0%. The overall diagnostic accuracy was 91.5%.

ROC analysis demonstrated an area under the curve (AUC) of **0.955**, indicating excellent discriminatory performance of intraoperative frozen-section examination in distinguishing positive from negative margins, with permanent-section histopathology used as the reference standard (**Table 4 & Figure#1**). Overall, the findings demonstrated a high level of agreement between intraoperative frozen-section assessment and the final permanent-section histopathological diagnosis.

Table#1: Demographic/Clinical Data of the Patients

Demographic/Clinical Data of the Patients	n (%)/Mean ± SD
Age (years)	
≤40	34 (14.5%)
41–50	63 (26.9%)
51–60	106 (45.3%)
>60	31 (13.2%)
Gender	
Male	130 (55.6%)
Female	104 (44.4%)
Tumor site	
Buccal mucosa	133 (56.8%)
Tongue	59 (25.2%)
Maxilla	19 (8.1%)
Mandible	23 (9.8%)
Tumor size	
≤4 cm	145 (62.0%)
>4 cm	89 (38.0%)
TNM stage	
Stage I	82 (35.0%)
Stage II	115 (49.1%)
Stage III	23 (9.8%)

Demographic/Clinical Data of the Patients	n (%)/Mean ± SD
Stage IV	14 (6.0%)
Histological grade	
Grade 1	66 (28.2%)
Grade 2	132 (56.4%)
Grade 3	36 (15.4%)
Frozen-section margin	
Positive	117 (50.0%)
Negative	117 (50.0%)
Permanent-section margin	
Positive	125 (53.4%)
Negative	109 (46.6%)

Table#2: Comparison of Frozen-Section Results with Permanent-Section Histopathological Diagnosis

Frozen-section result	Permanent-section positive	Permanent-section negative	Total
Positive	111 (TP)	6 (FP)	117
Negative	14 (FN)	103 (TN)	117
Total	**125**	**109**	**234**

Table#3: Diagnostic Accuracy of Frozen-section Examination using Permanent-Section Histopathology as the Reference Standard

Diagnostic parameter	Results
Sensitivity	88.8%
Specificity	94.5%
Positive predictive value	94.9%
Negative predictive value	88.0%
Diagnostic accuracy	91.5%

Table 4. Receiver Operating Characteristic (ROC) Analysis of Intraoperative Frozen-Section Examination Using Permanent-Section Histopathology as the Reference Standard

Measures	Results/Interpretation
Area under ROC curve (AUC)	0.916
Interpretation	Excellent discriminatory performance
Reference standard	Permanent-section histopathology
Index test	Intraoperative frozen section

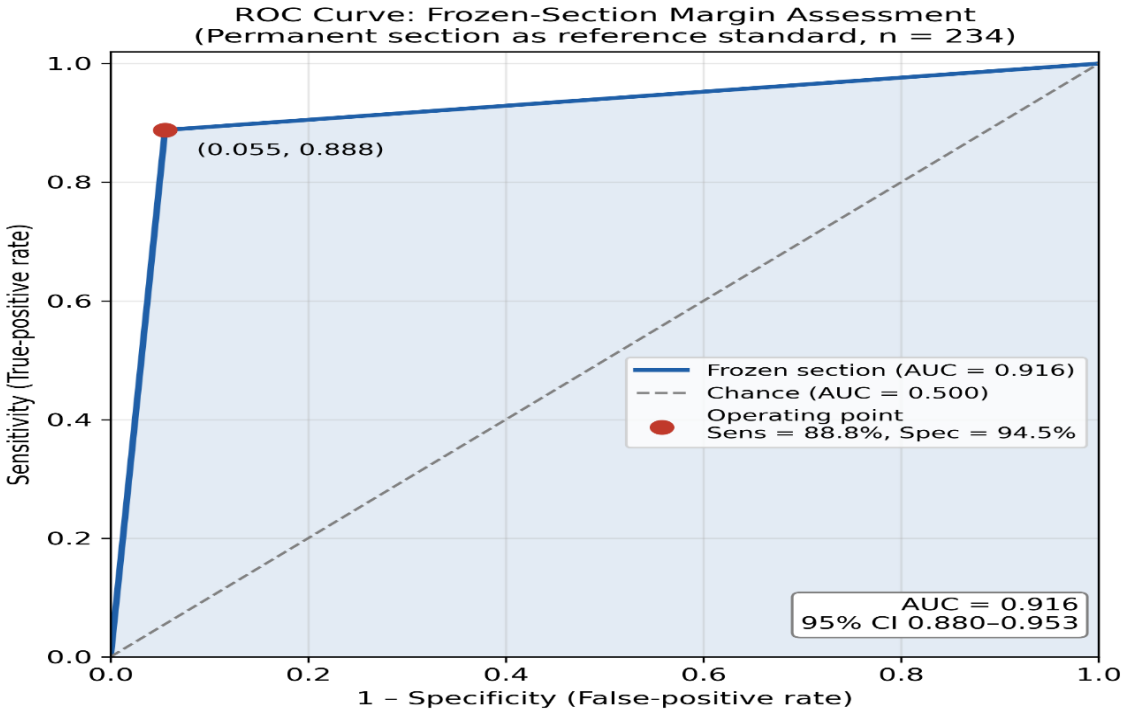

Figure#1: Receiving Operative Curve for Frozen-section Examination using Permanent-Section Histopathology as the Reference Standard.

Discussion

Confirming that a resection margin is truly clear while the patient is still under anesthesia is one of the harder judgments in oral cancer surgery, and frozen-section examination is the tool most surgeons lean on for it.[6,8] Against permanent-section histopathology, frozen section in our 234 patients showed a sensitivity of 88.8%, a specificity of 94.5%, a positive predictive value (PPV) of 94.9%, a negative predictive value (NPV) of 88.0% and an overall accuracy of 91.5%. The area under the ROC curve was 0.916 (95% CI 0.880–0.953), which is excellent discrimination. Because a frozen-section report is simply positive or negative, the curve has a single operating point, so this AUC is just the mean of sensitivity and specificity.

These figures are almost identical to those of Ali et al.,[10] who studied 251 patients with oral squamous cell carcinoma and reported a sensitivity of 88.81%, specificity of 94.84%, PPV of 95.20%, NPV of 88.10% and accuracy of 91.63%. Our case mix was similar too: buccal mucosa (56.8%) and tongue (25.2%) made up most tumors, close to the 57% and 25% seen by Wasif et al.,[6] which fits the widespread use of chewed tobacco and areca nut in South Asia.[7] A recent meta-analysis pooled a sensitivity of 0.78, a specificity of 0.98 and an AUC of 0.955;[11] our sensitivity is somewhat higher than the pooled value, and our specificity a little lower. Individual series are far more scattered. Sensitivity was 58.3% for Mahto et al.[12] and 66.5% for Tapase et al.,[13] whose patients had early T1–T2 N0 disease. Neumann et al.[14] reported 83.3%, Nentwig et al;[15] 50% and Du et al,[16] working with more than a thousand specimens, 83.1%. At the extremes, Wasif et al;[16] found 50% and Ferrari et al;[17] only 13.8%, while Demir et al;[8] reported 99%. Specificity, by contrast, stayed between 96% and 100% in nearly all of these, and our 94.5% sits at the lower end of that range.

Several things probably explain the spread in sensitivity. One is how positive margins are counted and how common they are. When margins are analyzed one by one and nearly all are negative, as in the Karachi series (428 of 432

margins negative on frozen section),[6] or when few patients have a positive margin, as in the German cohort (3.8%),[14] a handful of misses is enough to drag sensitivity down while specificity drifts toward 100%. Positive margins were common in our cohort (53.4% on permanent section), which steadies the sensitivity estimate but also means predictive values cannot be compared directly across studies, because PPV and NPV move with prevalence. Sampling is another. A frozen section examines only a small part of a margin, and tumour that is missing from the block, or appears only on deeper levels, will be overlooked. In the large series of Layfield et al;[18] (1,796 frozen–permanent pairs, 97% concordance) most errors were false negatives and most of those were due to sampling. Dayal et al;[14] in a general surgical series, put half of their discordances down to interpretation and a quarter each to block and specimen sampling, and Eichinger et al;[1] described tumour absent from the frozen block in discordant orbital specimens. Heavy inflammation can hide tumour cells, as in the single discordant case of Ayyagari et al;[2] and freezing artefact degrades morphology further.[8] Mechanisms like these are likely behind many of our 14 false-negative margins, although confirming that would need a re-review of the discordant slides. Technique and case mix matter as well: Demir et al;[8] found that agreement improved as more frozen sections were taken and advised a specimen-driven approach, and both Ali et al;[10] and Ferrari et al;[17] showed that accuracy varies with tumour stage, being lower in advanced disease.

Reports from other sites give a rough benchmark, though they are not directly comparable. Mixed-site series have reported an accuracy of 95.5% (sensitivity 89.5%, PPV 96.7%, NPV 94.9%)[5] and a concordance of 99.0%,[3] and frozen sections of orbital lesions matched the final diagnosis in 91.0% of specimens.[1] Most of these are questions of diagnosis, whereas margin assessment is harder: in a large breast cancer registry, frozen section did well for sentinel nodes but was judged less than optimal for margins.[9] Our accuracy of 91.5% is therefore lower than the headline figures of mixed series, yet in line with the oral cancer series of Ali et al.[10]

In practice the two kinds of error matter differently. Only 6 of our 117 positive frozen margins were false positives (5.1%), so a positive report can be acted on at once. The 14 false negatives are more troubling, because they make up 12.0% of margins reported as clear. A negative frozen section is reassuring but not a guarantee, and it should be read alongside the final histopathology and the clinical picture, as Wasif et al;[6] also stressed. There is a fair question, too, about whether accuracy translates into benefit. Gerber et al;[19] found that frozen section did not significantly change final margin status in 178 patients with oral or lip carcinoma, and a recent meta-analysis found no clear advantage over gross examination alone for margin status, recurrence or survival, although the evidence was of low certainty.[20] Nentwig et al;[15] add a caution: eight of the 19 margins that were positive on frozen section stayed positive despite immediate re-resection, and those patients fared worse. Diagnostic accuracy is therefore necessary, but not sufficient, for a useful margin strategy.

This study has limitations. Margin status was reduced to positive or negative, so close margins (under 5 mm) were not assessed, and we did not follow patients for recurrence or survival, which is exactly the gap left by the studies above. Permanent sections are also a sampling exercise, so some discordant results may reflect the limits of the reference standard as much as those of the frozen section. Overall, frozen section proved accurate and dependable for intraoperative margin assessment in oral cancer, with performance that matches regional[10] and pooled[10] data; where sensitivity is the main worry, taking additional sections from the specimen[8] is a practical step. Larger multicentre studies with margin mapping and outcome data should settle how far a frozen-section result ought to drive further resection.

Conclusion:

Intraoperative frozen-section examination demonstrated high diagnostic accuracy in the assessment of surgical margins, with a sensitivity of 88.8%, specificity of 94.5%, and overall diagnostic accuracy of 91.5%. The AUC of 0.955 further

indicated excellent discriminatory performance when compared with permanent-section histopathology. These findings suggest that frozen-section examination can provide reliable intraoperative information regarding margin status and may assist surgeons in making timely decisions during tumour resection. However, permanent-section histopathology remains the definitive reference standard for final margin assessment.

REFERENCES

1. Eichinger SE, Heymann HB, Mbagwu M, Knezevic A, Bryar PJ. Correlation between frozen section and permanent histopathologic diagnoses in adult orbital lesions. Ocul Oncol Pathol. 2022;8(2):141-7. doi:10.1159/000521075
2. Ayyagari S, Potnuru A, Saleem SA, Marapaka P. Analysis of frozen section compared to permanent section: a 2 year study in a single tertiary care hospital. J Pathol Nepal. 2021;11(2):1854-8. doi:10.3126/jpn.v11i2.37681
3. Basharat R, Iqbal M, Aslam H, Iqbal M, Kamal F. Diagnostic accuracy of frozen section: experience at Fatima Jinnah Medical University, Lahore. J Fatima Jinnah Med Univ. 2018;12(4):156-60.
4. Dayal A, Shah RJ, Joshi D, Patel SM. Diagnostic accuracy of frozen section in surgical diseases with critical evaluation of disconcordant reports. Natl J Lab Med. 2019;8(2):PO11-5. doi:10.7860/NJLM/2019/38380:2346
5. Bharadwaj BS, Deka M, Salvi M, Das BK, Goswami BC. Frozen section versus permanent section in cancer diagnosis: a single centre study. Asian Pac J Cancer Care. 2022;7(2):247-51. doi:10.31557/apjcc.2022.7.2.247-251
6. Wasif M, Mughal A, Hussain M, Zaidi M, Awan MS, Sidddique S, et al. The utility of frozen sections in the evaluation of clear margins in oral squamous cell carcinomas: a cross-sectional study from a tertiary care center. Cureus. 2022;14(2):e22308. doi:10.7759/cureus.22308
7. Barsouk A, Aluru JS, Rawla P, Saginala K, Barsouk A. Epidemiology, risk factors, and prevention of head and neck squamous cell carcinoma. Med Sci (Basel). 2023;11(2):42. doi:10.3390/medsci11020042
8. Demir B, Incaz S, Uckuyulu EI, Oysu C. Accuracy of frozen section examination in oral cavity cancers. Ear Nose Throat J. 2022;101(8):NP354-7. doi:10.1177/0145561320967334
9. Namdar ZM, Omidifar N, Arasteh P, Akrami M, Tahmasebi S, Nobandegani AS, et al. How accurate is frozen section pathology compared to permanent pathology in detecting involved margins and lymph nodes in breast cancer? World J Surg Oncol. 2021;19(1):261. doi:10.1186/s12957-021-02365-5
10. Ali JP, Mallick BA, Rashid K, Malik UA, Hashmi AA, Zia S, et al. Diagnostic accuracy of intraoperative frozen section for margin evaluation of oral cavity squamous cell carcinoma. BMC Res Notes. 2024;17(1):43. doi:10.1186/s13104-024-06698-8
11. Abbas R, Garg A, Kumar P, Augustine J, Urs AB. Reliability of frozen section in detecting tumor-free margins in oral squamous cell carcinoma: a systematic review and meta-analysis. Oral Oncol. 2026;176:107952. doi:10.1016/j.oraloncology.2026.107952

12. Mahto SK, Kashyap A, Paswan MK, Banerjee S, Patra S. Intraoperative assessment of margin accuracy in patients diagnosed with oral squamous cell carcinoma in a tertiary hospital of Jharkhand: frozen section versus histopathology. Cureus. 2024;16(4):e58345. doi:10.7759/cureus.58345
13. Tapase TP, Patra RK, Kisku DK, Badhai SK, Panigrahi SK, Bhoopathy G, et al. Intraoperative assessment of margin accuracy in early oral squamous cell carcinoma (cT1, T2, N0): clinical versus frozen section analysis. Cureus. 2023;15(3):e36699. doi:10.7759/cureus.36699
14. Neumann F, Straub X, Mrosk F, Rubarth K, Wolfsberg J, Piwonski I, et al. Resection status and margin control in intraoperative frozen sectioning analysis of oral squamous cell carcinoma. Oral Maxillofac Surg. 2024;28(3):1209-18. doi:10.1007/s10006-024-01238-x
15. Nentwig K, Unterhuber T, Wolff KD, Ritschl LM, Nieberler M. The impact of intraoperative frozen section analysis on final resection margin status, recurrence, and patient outcome with oral squamous cell carcinoma. Clin Oral Investig. 2021;25(12):6769-77. doi:10.1007/s00784-021-03964-y
16. Du E, Ow TJ, Lo YT, Gersten A, Schiff BA, Tassler AB, et al. Refining the utility and role of frozen section in head and neck squamous cell carcinoma resection. Laryngoscope. 2016;126(8):1768-75. doi:10.1002/lary.25899
17. Ferrari L, Pérez Salazar F, Cariati P, Fernández Solis J, Pulgar Encinas RM, Ferrari S, et al. Impact of intraoperative frozen section analysis on outcome in oral squamous cell carcinoma. J Craniomaxillofac Surg. 2025;53(6):840-3. doi:10.1016/j.jcms.2025.02.025
18. Layfield EM, Schmidt RL, Esebua M, Layfield LJ. Frozen section evaluation of margin status in primary squamous cell carcinomas of the head and neck: a correlation study of frozen section and final diagnoses. Head Neck Pathol. 2018;12(2):175-80. doi:10.1007/s12105-017-0846-6
19. Gerber S, Gengler C, Grätz KW, Kruse AL. The impact of frozen sections on final surgical margins in squamous cell carcinoma of the oral cavity and lips: a retrospective analysis over an 11 years period. Head Neck Oncol. 2011;3:56. doi:10.1186/1758-3284-3-56
20. Armstrong LTD, Beech NM, Breik O, Batstone MD. Utility of frozen section pathology in oral squamous cell carcinoma: a systematic review and meta-analysis. Int J Oral Maxillofac Surg. 2026;55(1):1-9. doi:10.1016/j.ijom.2025.08.006