The Research of Medical Science Review
ISSN: 3007-1208 & 3007-1216 Volume 3, Issue 6, 2025

QUANTIFYING VERSALITY AND ONCOLOGICAL OUTCOMES OF SUBMENTAL FLAP IN ORAL CANCER

Dr Hafsa Maqbool[*1], Professor. Dr Suneel Kumar Punjabi[2], Dr Ume Farwah[3], Dr Mariyam Memon[4], Dr Hina Rehman[5]

[1,3,5]*Post graduate resident oral and maxillofacial surgery, Oral and maxillofacial surgery Institute of Dentistry, Liaquat University of medical and health sciences, jamshoro*
[2]*Professor Oral and maxillofacial surgery Institute of Dentistry, Liaquat University of medical and health sciences, jamshoro*
[4]*Msc oral and maxillofacial surgery, Oral and maxillofacial surgery Institute of Dentistry, Liaquat University of medical and health sciences, Jamshoro.*

DOI: https://doi.org/10.5281/zenodo.23469653

Keywords
Submental Island Flap; Oral Squamous Cell Carcinoma; Oral Cavity; Reconstructive Surgical Procedures; Surgical Flaps; Postoperative Complications; Treatment Outcome; Aesthetic Outcome; Local Recurrence.

Article History
Received: 20 April 2025
Accepted: 15 May 2025
Published: 03 June 2025

Copyright @Author
Corresponding Author: *
Dr Hafsa Maqbool

Abstract

Objective: *To evaluate the clinical, functional, aesthetic, and oncological outcomes of submental island flap (SMIF) reconstruction for oral cavity defects following excision of primary oral squamous cell carcinoma.*

Methods: *This descriptive study was conducted over 18 months at Liaquat University of Medical and Health Sciences, Jamshoro/Hyderabad, after ethical approval. A total of 179 patients aged 30–60 years with biopsy-proven T1 or T2 oral squamous cell carcinoma underwent reconstruction with a SMIF. Patients were selected through consecutive sampling. Flap coverage and viability were assessed clinically using flap colour, capillary refill, scratch test, and suture-line integrity during the first postoperative week. Aesthetic outcomes, including whistling, smiling, beard appearance in males, and donor-site scar appearance, were assessed at day 7, 3 months, and 6 months. Postoperative complications and oncological outcomes were also recorded.*

Results: *The mean age was 51.8±12.4 years, with 120 (67%) males. Complete defect coverage was achieved in 170 (95%) patients. Positive flap versatility was observed in 170 (95%) cases immediately after surgery and in 156 (87.2%) on day 7. Overall postoperative flap-related complications occurred in 36 (20%) patients. Aesthetic scores showed improvement during follow-up, with mean whistling, smiling, beard appearance, and scar scores increasing between day 7 and 6 months. During follow-up, 134 (74.9%) patients remained alive and disease-free. Local recurrence occurred in 9 (5.0%), regional/nodal recurrence in 29 (16.2%), and locoregional recurrence in 18 (10.1%) patients. No distant metastasis was observed.*

Conclusion: *SMIF provided satisfactory defect coverage with generally favourable early flap viability, improving aesthetic outcomes, and acceptable short-term oncological outcomes in selected patients with T1–T2 oral squamous cell carcinoma.*

INTRODUCTION

Oral cancer is a major global health burden and is among the common malignancies affecting the middle- and older-age population. According to the World Health Organization, oral cancer is among the leading cancers worldwide, with a substantial proportion of cases occurring in developing countries.[1,2] The disease commonly involves the labial and buccal mucosa, floor of the mouth, gingiva, palate, and tongue.[2] Major risk factors include tobacco use, smoking, excessive alcohol consumption, and human papillomavirus (HPV) infection, with a higher incidence reported among men than women.[2,3] Early diagnosis and appropriate treatment are important determinants of outcome, with substantially better survival reported when oral cancer is detected at an early stage.[1] Squamous cell carcinoma is the predominant histological type, and cervical lymph node status remains one of the most important prognostic factors for recurrence and survival.[4]

The primary treatment for resectable oral cavity carcinoma is surgical excision with adequate oncological margins.[3,5] However, tumour resection frequently results in complex three-dimensional defects involving the tongue, floor of the mouth, buccal mucosa, palate, and adjacent facial structures. Reconstruction of these defects is technically demanding and has a direct impact on functional outcomes, facial aesthetics, quality of life, and psychological well-being.[2,5,6] Microvascular free flaps, particularly the radial forearm free flap (RFFF), are widely regarded as the standard reconstructive option for extensive oral cavity defects. However, their use requires specialised surgical expertise, prolonged operative time, appropriate infrastructure, intensive postoperative monitoring, and prolonged hospitalization, which may increase morbidity and healthcare costs.[7,8]

The submental island flap (SMIF), first described by Martin et al., has emerged as an alternative regional flap for reconstruction of head and neck defects.[3] It can provide tissue of adequate size and pliability for reconstruction of defects involving the lower face, tongue, palate, buccal mucosa, floor of the mouth, gingiva, and laryngeal region, with reported dimensions of up to approximately 15 × 6 cm.[3] The SMIF offers several advantages, including relatively simple and rapid harvesting, good tissue pliability, low donor-site morbidity, concealed donor-site scarring, and satisfactory functional and aesthetic outcomes.[3] Its use may therefore be particularly relevant in settings where the resources and expertise required for microvascular reconstruction are limited.

Despite these advantages, concerns remain regarding the oncological safety of SMIF, particularly its relationship with level I cervical lymph nodes and the potential risk of compromising lymphatic clearance during flap harvest.[9,10] Shires et al. reported relatively high flap-related failure and complication rates despite the consistent vascular anatomy of the flap.[9] Furthermore, concerns have been raised regarding the potential transfer of metastatic lymphatic tissue with the flap in patients with cervical nodal disease.[9] Therefore, appropriate patient selection and careful assessment of cervical lymph node status remain essential when considering SMIF reconstruction.

There remains a need for further evidence regarding the functional, aesthetic, oncological, and postoperative outcomes of SMIF reconstruction, particularly in the local population. The present study therefore aimed to evaluate the outcomes of SMIF reconstruction for oral cavity defects, with particular emphasis on defect coverage, aesthetic results, oncological safety, and postoperative complications. The findings may provide locally relevant evidence regarding the feasibility and effectiveness of SMIF as a reconstructive option for patients undergoing surgery for oral cavity malignancy.

Methodology:

This descriptive study was conducted over a period of eighteen months following approval of the synopsis by the Ethical review committee of the hospital in the Departments of Oral and Maxillofacial Surgery and Plastic Surgery at Liaquat University of Medical and Health Sciences

(LUMHS), Jamshoro/Hyderabad. Informed consent was obtained from all participants before enrolment. A total sample size of 179 patients was calculated using OpenEpi at a 95% confidence level, assuming an anticipated frequency of 3%[6] with a 2.5% absolute precision and a design effect of 1. Patients were enrolled through non-probability consecutive sampling.

Patients aged 30–60 years of either sex, with American Society of Anesthesiologists (ASA) physical status I–III and biopsy-proven primary oral squamous cell carcinoma of T1 or T2 stage, were included. Eligible patients had primary tumors involving the anterior two-thirds of the oral cavity without involvement of the floor of the mouth and had no radiological evidence of level I cervical lymph node involvement on contrast-enhanced computed tomography (CT). Patients who were fit for general anaesthesia and willing to provide informed consent were included. Patients with severe uncontrolled systemic disease, coagulation disorders, pregnancy, previous therapeutic radiotherapy to the head and neck, recurrent oral cancer, use of systemic corticosteroids, immunosuppressive agents, bisphosphonates or chemotherapeutic agents, palpable or radiologically proven level I lymph nodes, tumour involvement of the floor of the mouth, or restricted mouth opening defined as inability to insert three fingers between the upper and lower central incisors were excluded.

All patients underwent clinical assessment, baseline investigations, and preoperative anaesthetic evaluation. The diagnosis of oral cancer was confirmed by histopathological examination of an incisional biopsy, and tumour stage was determined according to the eighth edition of the TNM classification. Preoperative assessment of marginal mandibular nerve function was performed by evaluating whistling and smiling, and standardized photographs were obtained for subsequent comparison of facial symmetry and beard appearance. Patients were counselled regarding the surgical procedure, expected duration, and potential intraoperative and postoperative complications, and written informed consent was obtained. General anaesthesia was administered according to standard institutional protocols.

Following surgical excision of the primary tumour with adequate oncological margins, the submental island flap (SMIF) was designed according to the size and location of the resultant defect. The flap was harvested while preserving its vascular pedicle, and neck dissection was performed as indicated. Frozen-section examination was performed for the surgical margins and level IA lymph node. The resulting oral cavity defect was reconstructed using the SMIF, which was inset without undue tension and secured with sutures. Standard postoperative care was provided, and patients were monitored for flap viability, postoperative complications, and functional and aesthetic outcomes.

Flap versatility was assessed based on the ability of the SMIF to provide adequate defect coverage and achieve satisfactory colour match with the contralateral oral mucosa. The flap colour was assessed by an experienced surgeon who was not involved in the study, and was categorized as pink/red, pale/white, or blue/purple in comparison with the contralateral side. Adequate defect coverage was assessed intraoperatively by measuring the defect and flap dimensions using a stainless-steel ruler and postoperatively by evaluating the presence of tension or dehiscence at the suture line. Successful coverage without flap dehiscence was considered positive flap versatility, whereas inadequate coverage or flap failure was considered negative versatility. Flap viability was further assessed clinically using colour, capillary refill, and scratch tests. Assessments of flap colour, size, viability, and postoperative complications were performed immediately after surgery and on postoperative days 1, 3, and 7.

Aesthetic outcomes were assessed by an experienced surgeon independent of the principal investigator at postoperative days 7 and at 3 and 6 months. The assessment included whistling, smiling, beard appearance in male patients, and donor-site scar appearance. Each parameter was scored from 0 to 3, with higher scores indicating better aesthetic outcomes. Whistling was assessed

according to lip symmetry and the ability to form a rounded shape, while smiling was assessed according to symmetry of the angle of the mouth compared with preoperative photographs. Beard changes in male patients were graded according to the degree of postoperative beard loss. Donor-site appearance was assessed according to the overall appearance and visibility of the scar. Scores obtained at the three follow-up assessments were summed for each parameter, with higher cumulative scores indicating better aesthetic outcomes.

Postoperative complications were recorded immediately after surgery and on postoperative days 1, 3, and 7. Complications were categorized as mild, moderate, or severe. Mild complications were defined as flap dehiscence not requiring procedural intervention; moderate complications included partial flap necrosis requiring bedside debridement; and severe complications included complications requiring operative intervention, such as pedicle revision, extensive debridement, or complete flap failure. Overall complication status was recorded as positive when any flap-related complication was present and negative when no complication occurred.

Oncological safety was assessed during follow-up at 3 and 6 months. Local recurrence was defined as recurrence at the primary tumor site, whereas regional recurrence was defined as recurrence in the cervical lymph nodes. Distant metastatic disease was defined as the development of tumor at a site distant from the primary lesion or regional lymph nodes. Disease-free status was defined as the absence of local, regional, or distant recurrence during follow-up. Oncological outcomes were assessed clinically and confirmed by appropriate imaging, including CT scans, when indicated.

Data were analysed using SPSS version 26.0. Quantitative variables were expressed as mean ± standard deviation. Categorical variables, including sex, flap viability, flap complications, recurrence, metastatic disease, and disease-free status, were presented as frequencies and percentages and in pie chart and histogram.

Results:

A total of 179 patients with primary oral squamous cell carcinoma (OSCC) underwent reconstruction with a submental island flap. The mean age was 51.8±12.4 years, with a male predominance (120; 67%). Females accounted for 59 (33%) patients. Among the reported habits, ghutka use was the most frequent (57; 31.7%), followed by chalia (42; 23.7%) and smoking (39; 22%). Naswar use was reported in 16 (9%) patients, while 9 (5%) reported alcohol consumption and 16 (9%) had other habits. The distribution of these habits is shown in **Figure 1**. Co-morbidities were present in 108 (60.3%) patients, while 71 (39.7%) had no documented co-morbidity (**Figure 2**). Based on ASA classification, 71 (39.7%) patients were classified as ASA-I, 88 (49.2%) as ASA-II and 20 (11.2%) as ASA-III **(Table 1).**

Most patients presented with T2 disease, accounting for 114 (63.6%) cases, whereas 65 (36.3%) had T1 tumours. The buccal mucosa was the commonest tumour site (72; 40.2%), followed by the tongue (62; 34.6%) and gingiva/alveolus (45; 25.1%) **(Table 1).**

The mean defect size was 33.3±15 cm^2. A flap size of 30–50 cm^2 was required in more than half of the patients (98; 55%), while 45 (25%) had a flap measuring less than 30 cm^2 and 36 (20%) required a flap larger than 50 cm^2. Suture-line tension was noted in 22 (12.3%) patients and was absent in the remaining 157 (87.7%). Frozen-section examination showed negative surgical margins in 161 (89.9%) patients, while 18 (10.1%) had positive margins. Similarly, level IA lymph-node frozen sections were negative in 162 (90%) patients and positive in 17 (10%). Complete coverage of the defect was achieved in 170 (95%) cases **(Table 2).**

Early postoperative assessment showed that the majority of flaps remained viable during the first postoperative week (Table 3). Immediately after surgery, flap versatility was considered positive in 170 (95%) patients. This proportion was 168 (93.9%) on day 1, 165 (92.2%) on day 3 and 156 (87.2%) on day 7. A pink or red flap colour was observed in 161 (90%) patients immediately after

surgery and remained evident in 152 (84.9%) by day 7. Normal capillary refill showed a similar pattern, being present in 161 (90%) patients initially and in 152 (84.9%) on day 7.

The scratch test was positive in 175 (98%) patients immediately after surgery, decreasing to 172 (96%) on day 1, 168 (94%) on day 3 and 161 (90%) on day 7. Suture-line integrity was maintained in 170 (95%) patients during the immediate postoperative assessment and on day 1, while 161 (89.9%) patients had an intact suture line on days 3 and 7. Wound dehiscence was observed in 4 (2.2%) patients immediately after surgery and increased to 18 (10.1%) by day 7.

No evidence of flap loss was noted in 175 (97.8%) patients immediately after surgery. This decreased to 156 (87.2%) patients by day 7. Mild flap loss was observed in 2 (1.1%) patients initially and in 7 (3.9%) patients on day 7, while moderate flap loss increased from 2 (1.1%) to 9 (5.0%). Severe flap necrosis was not observed during the immediate postoperative assessment or on day 1, but was recorded in 2 (1.1%) patients on day 3 and 23 (12.8%) patients by day 7 **(Table 3).**

Postoperative flap-related complications were recorded in 36 (20%) patients, whereas 143 (80%) patients had no documented complication **(Table 4).**

A progressive improvement in the recorded aesthetic parameters was observed during follow-up **(Table 5)**. The mean whistling score increased from 7.2±1.4 on day 7 to 8.0±1.1 at three months and 8.3±1.0 at six months. The mean smiling score similarly increased from 7.1±1.4 at day 7 to 8.0±1.0 at three months and 8.2±0.9 at six months. Among male patients, the mean beard appearance score improved from 7.4±1.3 at day 7 to 8.1±0.9 at three months and 8.5±0.8 at six months. The mean incisional scar score also showed improvement over time, increasing from 6.8±1.5 at day 7 to 7.7±1.1 at three months and 8.0±1.0 at six months.

Overall, positive flap versatility was documented in 170 (95%) patients. During the reported follow-up, 134 (74.9%) patients remained alive and disease-free. Local recurrence occurred in 9 (5.0%) patients, while regional/nodal recurrence was reported in 29 (16.2%). Locoregional recurrence was documented in 18 (10.1%) patients. No patient developed distant metastasis. Nine (5.0%) patients were recorded as having died or were lost to follow-up **(Table 6 & Figure 3).**

Table#1: Demographic & Clinical Data of the Participants (n=179)

Demographic & Clinical Data	(mean ± sd)/ n(%)
Age (Years)	51.8 ± 12.4
Gender	
• Male	120 (67%)
• Female	59 (33%)
Habits	
• Ghutka	57 (31.7%)
• Chalia	42 (23.7%)
• Smoking	39 (22%)
• Alcohol	9 (5%)
• Naswar	16 (9%)
• Others	16 (9%)
Co-morbidiities:	
Yes	108 (60.3%)
No	71 (39.6%)

ASA Status • ASA-I • ASA-II • ASA-III	 71 (39.7%) 88 (49.2%) 20 (11.2%)
Tumor Stage • T1 • T2	 65 (36.31%) 114 (63.6%)
Tumor Site • Buccal mucosa • Tongue • Gingiva/alveolus	 72 (40.2%) 62 (34.6%) 45 (25.1%)

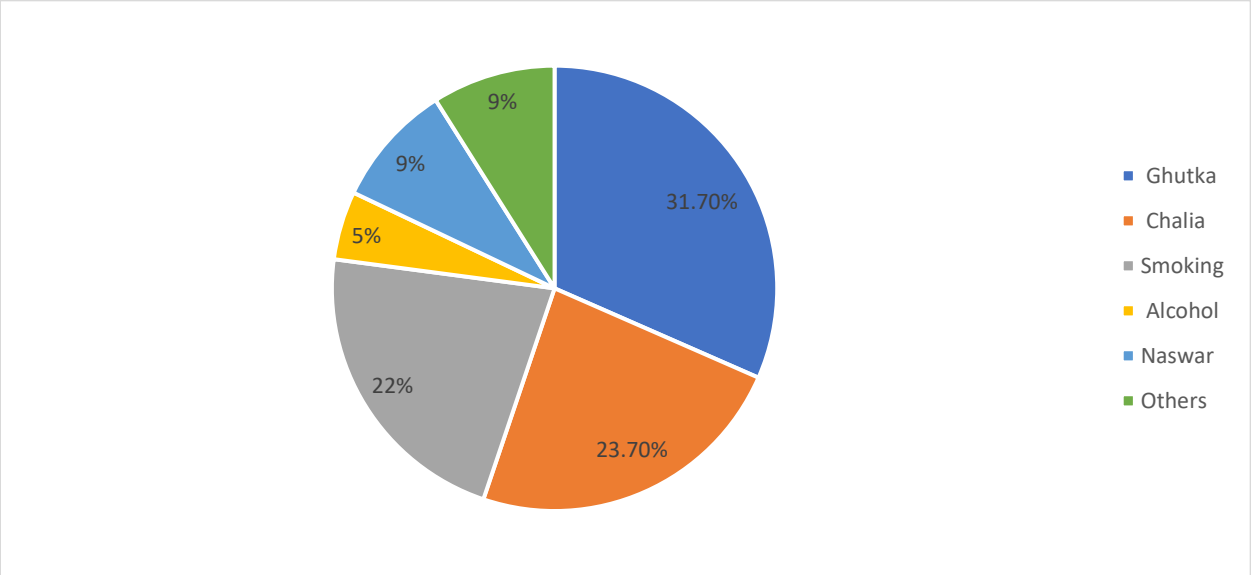

Figure#1: Distribution of the Patients according Habits

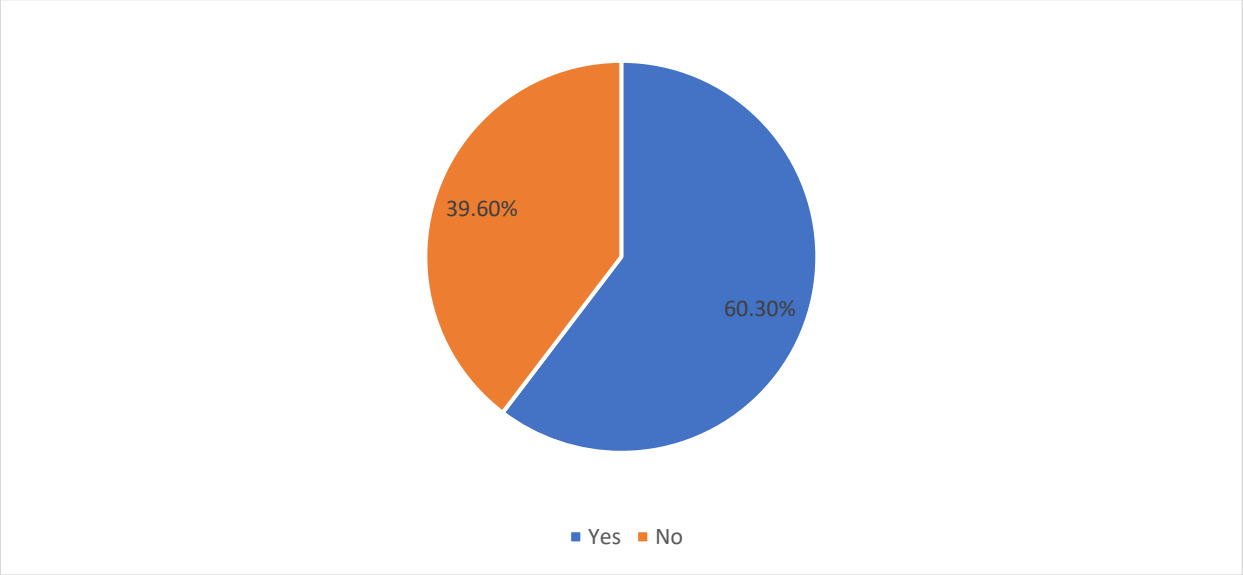

Figure#2: Co-morbidities among the patients of primary oral squamous cell carcinoma

Table#2: Operative and flap characteristics (n=179)

Variables	(mean ± sd)
Defect size (cm)	33.3 ± 15 cm^2
Flap size categories • Small (< 30 cm^2) • Medium (30–50 cm^2) • Large (>50 cm^2)	 45 (25%) 98 (55%) 36 (20%)
Tension at suture line • Absent • Present	 157 (87.7%) 22 (12.3%)
Frozen section of surgical margins • Negative • Positive	 161 (89.9%) 18 (10.1%)
Level IA lymph node frozen section • Negative • Positive	 162 (90%) 17 (10%)
Flap coverage • Complete • Incomplete	 170 (95%) 9 (5%)

IEER
Institute for Excellence in Education & Research

Table#3: Submental Island flap versatility and viability

Outcome	Immediate post-operative n (%)	Day 1 n (%)	Day 3 n (%)	Day 7 n (%)
Flap versatility				
Positive	170 (95.0%)	168 (93.9%)	165 (92.2%)	156 (87.2%)
Negative	9 (5.0%)	11 (6.1%)	14 (7.8%)	23 (12.8%)
Flap colour				
Pink/red	161 (90.0%)	161 (90.0%)	158 (88.3%)	152 (84.9%)
Pale/white	9 (5.0%)	9 (5.0%)	7 (3.9%)	7 (3.9%)
Blue/purple	4 (2.2%)	4 (2.2%)	5 (2.8%)	5 (2.8%)
Capillary refill				
Normal	161 (90.0%)	161 (90.0%)	158 (88.3%)	152 (84.9%)
Delayed/absent	9 (5.0%)	9 (5.0%)	11 (6.1%)	14 (7.8%)
Scratch test				
Positive	175 (98%)	172 (96%)	168 (94%)	161 (90%)
Negative	04 (2%)	07 (4%)	11 (6%)	18 (10%)
Suture-line integrity				
Intact	170 (95.0%)	170 (95.0%)	161 (89.9%)	161 (89.9%)
Dehiscence	4 (2.2%)	4 (2.2%)	13 (7.3%)	18 (10.1%)
Flap loss/necrosis severity				
No flap loss	175 (97.8%)	173 (96.6%)	169 (94.4%)	156 (87.2%)
Mild	2 (1.1%)	3 (1.7%)	4 (2.2%)	7 (3.9%)
Moderate	2 (1.1%)	3 (1.7%)	4 (2.2%)	9 (5.0%)
Severe	0 (0%)	0 (0%)	2 (1.1%)	23 (12.8%)

Table#4: Postoperative flap complications (n=179)

Complications	n (%)
Yes	36 (20%)
No	143 (80%)

Table#5: Aesthetic outcomes at follow-up

Aesthetic Parameters	Day 7 Mean ± SD	3 months Mean ± SD	6 months Mean ± SD
Whistling score	7.2 ± 1.4	8.0 ± 1.1	8.3 ± 1.0
Smiling score	7.1 ± 1.4	8.0 ± 1.0	8.2 ± 0.9
Beard appearance score*	7.4 ± 1.3	8.1 ± 0.9	8.5 ± 0.8
Incisional scar score	6.8 ± 1.5	7.7 ± 1.1	8.0 ± 1.0

*Applicable to male patients only

Table 6. Overall flap versatility and oncological outcomes (n = 179)

Outcomes	n (%)
Overall flap versatility – Positive	170 (95.0%)
No recurrence	134 (74.9%)
Local recurrence	9 (5.0%)
Regional/Nodal recurrence	29 (16.2%)
Locoregional recurrence	18 (10.1%)
Distant metastasis	0 (0%)
Alive and disease-free	134 (74.9%)
Death/lost to follow-up	9 (5.0%)

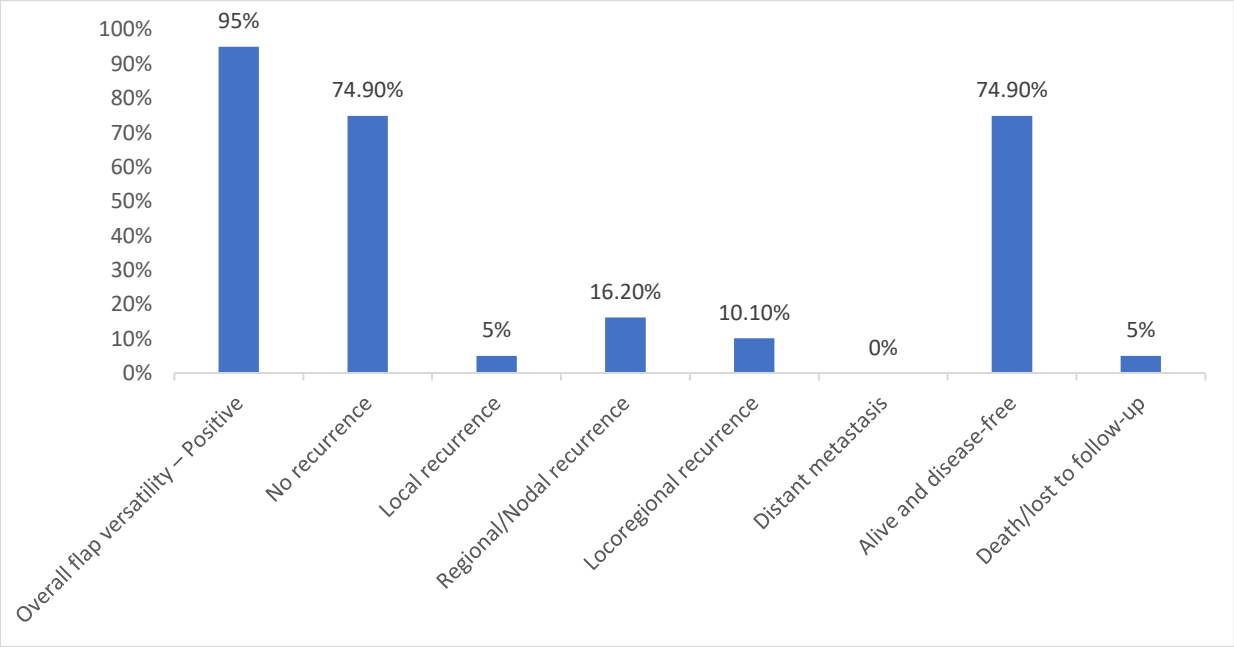

Figure#3: Overall flap versatility and oncological outcomes

Discussion

The present study evaluated the reconstructive, functional, aesthetic, and oncological outcomes of submental island flap (SMIF) reconstruction in 179 patients with primary oral squamous cell carcinoma. The mean age was 51.8±12.4 years, and males constituted 67% of the cohort. This demographic pattern is comparable with previous SMIF series, which have generally reported a male predominance and presentation during the fifth and sixth decades of life.[2,11,12] The relatively high prevalence of ghutka (31.7%) and chalia (23.7%) in our cohort also reflects the pattern of smokeless tobacco exposure commonly reported among patients with oral cancer in South Asian populations.

Buccal mucosa was the most common tumour site (40.2%), followed by the tongue (34.6%) and

gingiva/alveolus (25.1%). This distribution differs from some previous series in which the tongue was the predominant site.[2,13] Such differences may be related to variations in local risk factors, patient populations, and referral patterns. Most patients in the present study had T2 tumours (63.6%), with a mean defect size of 33.3±15 cm², indicating that SMIF was mainly used for moderate-sized oral defects.

The reconstructive outcomes were favourable, with complete defect coverage achieved in 170 (95%) patients. More than half of the patients required a flap measuring 30–50 cm², while suture-line tension was noted in only 22 (12.3%) patients. These findings support previous reports describing SMIF as a versatile regional flap for reconstruction of small- to moderate-sized oral defects.[8,11,13,14] The close proximity of the donor site to the oral cavity, adequate tissue availability, and avoidance of microvascular anastomosis are important practical advantages of the technique.[7,9] Recent clinical series have similarly reported satisfactory flap survival and functional outcomes following SMIF reconstruction. [13,14]

Early postoperative monitoring showed generally satisfactory flap viability. A positive scratch test was present in 175 (98%) patients immediately after surgery and remained positive in 161 (90%) by day 7. Normal flap colour and capillary refill were observed in 161 (90%) patients initially and in 152 (84.9%) at day 7. Flap-related complications occurred in 36 (20%) patients. Although these findings indicate generally satisfactory early flap performance, the progressive decline in some viability parameters highlights the importance of close postoperative monitoring. Reported complication rates vary across studies, partly because definitions of partial necrosis, flap compromise, and flap loss are not uniform.[5,11,13] In a multicentre study, Zhao et al. demonstrated that variations in vascular pedicle design could be used to accommodate different defect characteristics while maintaining satisfactory reconstructive outcomes.[5] Eldweny also reported good overall flap reliability in patients undergoing reconstruction for oral cavity carcinoma.[6]

The aesthetic outcomes showed gradual improvement during follow-up. The mean whistling score increased from 7.2±1.4 at day 7 to 8.3±1.0 at six months, while the smiling score increased from 7.1±1.4 to 8.2±0.9. Among male patients, the beard appearance score improved from 7.4±1.3 to 8.5±0.8, and the incisional scar score increased from 6.8±1.5 to 8.0±1.0. These findings suggest that functional and cosmetic recovery continues during the months following reconstruction, possibly reflecting resolution of postoperative oedema and progressive scar maturation. Previous studies have also reported satisfactory facial function, appearance, and low donor-site morbidity after SMIF harvesting.[10,12,13] In addition, recent evidence has demonstrated favourable oral diet outcomes following submental flap reconstruction, further supporting its functional value.[17]

The oncological findings are also encouraging. Negative surgical margins were achieved in 161 (89.9%) patients, while level IA lymph-node frozen sections were negative in 162 (90%). During follow-up, local recurrence occurred in 9 (5.0%) patients, regional/nodal recurrence in 29 (16.2%), and locoregional recurrence in 18 (10.1%); no distant metastasis was documented. These findings are within the range reported in contemporary studies evaluating the oncological safety of SMIF reconstruction.[7,11,15,16,19] Paydarfar et al., in a 10-year experience, found that SMIF could be used safely for appropriately selected head and neck cancer defects, while recent comparative studies have reported similar oncological outcomes between SMIF and free-flap reconstruction.[11,15] The study by Miao et al. also supports the oncological feasibility of pedicled SMIF reconstruction in selected patients with oral tongue squamous cell carcinoma.[16]

The possibility of occult or involved level I lymph nodes remains an important consideration when using a submental flap. This concern is related to the anatomical proximity of the flap pedicle to the submental and submandibular lymphatic basins. Therefore, appropriate preoperative staging, careful assessment of the neck, and oncologically

adequate neck dissection remain essential. Previous studies have shown that nodal involvement, rather than the reconstructive flap itself, is an important determinant of locoregional recurrence.[16,19] The extended follow-up study by Qayyum et al. likewise reported acceptable oncological outcomes following SMIF reconstruction, supporting its use when appropriate oncological precautions are taken.[15]

The recurrence pattern in the present study should therefore be interpreted in the context of tumour characteristics and nodal status. The local recurrence rate of 5.0% was relatively limited, whereas regional/nodal recurrence occurred in 16.2% of patients. Importantly, recurrence cannot be attributed to the flap alone, as tumour stage, pathological nodal status, margin status, tumour biology, and adjuvant treatment all influence oncological outcomes. A recent systematic review and meta-analysis by Taseen et al. reported a pooled locoregional recurrence rate of approximately 16% following SMIF reconstruction, indicating that recurrence rates observed in the present study are broadly comparable with the available literature.[18] Evidence from studies specifically examining T1–T2 oral squamous cell carcinoma has likewise supported the oncological safety of SMIF when appropriate patient selection and neck management are undertaken.[19]

Overall, the present study demonstrates that SMIF provided satisfactory reconstruction in 179 patients, with complete defect coverage in 95%, generally favourable early flap viability, progressive improvement in aesthetic outcomes, and no documented distant metastasis during the reported follow-up. The findings add to the growing evidence that SMIF can be a useful reconstructive option for appropriately selected oral cavity defects. Its proximity to the operative field, relatively straightforward harvest, and avoidance of microvascular anastomosis make it particularly practical when the defect is suitable for regional flap reconstruction. However, successful outcomes depend on careful patient selection, meticulous flap dissection and monitoring, adequate tumour clearance, and appropriate management of the neck.

Conclusion

The submental island flap provided reliable reconstruction for oral cavity defects in this series of 179 patients with primary OSCC. High rates of complete defect coverage, generally satisfactory flap viability, progressive improvement in aesthetic outcomes, and low local recurrence were observed. The findings support SMIF as a practical and versatile reconstructive option for appropriately selected patients, provided that careful flap planning, postoperative monitoring, adequate tumour clearance, and appropriate neck management are maintained.

Conflict of interest: Nil

Financial assistance: Nil

REFERENCES

Dixit S, Kumar A, Srinivasan K. A current review of machine learning and deep learning models in oral cancer diagnosis: recent technologies, open challenges, and future research directions. Diagnostics (Basel). 2023;13(7):1353.

Ramirez AT, Chiesa-Estomba CM, González-García JA. Submental artery island flap in oral cavity reconstruction: an observational, retrospective two-centre study. Int Arch Otorhinolaryngol. 2021;25(1):e71-e76.

Zaid AM, Elzahaby IA, Hossam A, Elbadrawy M. Submental island flap for reconstruction of oral cancer post-resection defects: surgical outcomes and oncological safety. Med J Cairo Univ. 2022;90(1):315-322.

Mittal GS, Bhutani H, Gautam A, Agarwal M. Clinical outcome and oncological safety of submental flap for reconstruction in head and neck cancer patients. J Oral Med Oral Surg Oral Pathol Oral Radiol. 2020;6(3):132-136.

Zhao J, Zeng W, Li K, Huang J, Tong MCF, Deng L, et al. Repair of postoperative defects of oral cancer with submental island flaps based on vascular pedicles of different states: a multicenter retrospective study. Sci Rep. 2022;12(1):21257.

Eldweny H. The reliability of submental flap for soft tissue reconstruction in patients with carcinoma of the oral cavity. Eur J Surg Oncol. 2023;49(8):1374-1380.

Sittitrai P, Ruenmarkkaew D, Kumkun C, Srivanitchapoom C. A retrospective propensity score-matched analysis of oncological and functional outcomes of submental island flap versus radial forearm free flap for oral cavity cancer reconstruction. BMC Oral Health. 2024;24(1):190.

Katre MI, Keche P, Gaikwad A, Deshmukh S. Versatility of the submental island flap in head and neck reconstruction. Int J Otorhinolaryngol Head Neck Surg. 2017;3(4):1072-1076.

Shires CB, Sebelik M. The submental flap: be wary. Clin Case Rep. 2022;10(1):e05260.

Lee JC, Lai WS, Kao CH, Hsu CH, Chu YH, Lin YS. Multiple-parameter evaluation demonstrates low donor-site morbidity after submental flap harvesting. J Oral Maxillofac Surg. 2013;71(10):1800-1808.

Paydarfar JA, Kahng PW, Polacco MA, Zhao W. The submental island flap in head and neck reconstruction: a 10-year experience examining application, oncologic safety, and role of comorbidity. Laryngoscope Investig Otolaryngol. 2022;7(2):361-368.

Shaikh M, Kumar K, Kannan R, Doctor A, Singh A, Pradhan SA. The submental flap for reconstruction of tongue defects: surgical outcome and quality of life assessment. Indian J Otolaryngol Head Neck Surg. 2023;75(4):2895-2900.

Kumar N, Singhal PM, Gora BS, Sharma S, Lakhera KK, Patel P, et al. Submental artery island flaps (SAIF) for oral cavity cancer: surgical technique and tertiary care experience. Indian J Otolaryngol Head Neck Surg. 2024;76(1):819-826.

Ma J, Zhai X, Huang M, Li P, Liang Y, Ouyang D, et al. The contralateral-based submental artery island flap: feasibility and oncological safety in oral cancer-related defect reconstruction. Clin Oral Investig. 2023;27(8):4747-4755.

Qayyum MU, Keerio AA, Zaheer R, Mushtaq U, Baig V, Hussain R, et al. The oncological safety of submental flap reconstruction in head-and-neck cancers: an extended follow-up study. J Cancer Allied Spec. 2024;10(2):573.

Miao HJ, Sun SK, Tian YY, et al. Oncologic safety of the pedicled submental island flap for reconstruction in oral tongue squamous cell carcinoma: an analysis of 101 cases. Oral Oncol. 2023;140:106395.

Wu MP, Sim ES, Goldsmith T, Kovoor M, Lin DT, Richmon JD, et al. Oral diet outcomes and tracheostomy avoidance after submental flap reconstruction of oral and oropharyngeal defects. Laryngoscope Investig Otolaryngol. 2025;10(5):e70271.

Taseen S, Qureshi MFH, Abbas M, Ghaloo SK, Wasif M, Iftikhar H, et al. Oncological safety of the submental artery island flap for oral reconstruction: a systematic review and meta-analysis. Head Neck. 2026;48(9):2470-2482.

Wang J, Tan Y, Shen Y, Lv M, Li J, Sun J. Oncological safety of submental island flap for reconstruction of pathologically node-negative and node-positive T1-2 oral squamous cell carcinoma-related defects: a retrospective study and comparison of outcomes. *Oral Oncol.* 2020;102:104507.

IEER
Institute for Excellence in Education & Research

Shen Z, Lu C, Huang L, Li N, Wang W, Jiang C. Assessment of surgical outcomes and oncological safety for submental artery perforator flap reconstruction after ablation of oral cancer. *Br J Oral Maxillofac Surg.* 2021;59(8):881-887

IEER
Institute for Excellence in Education & Research